

# Radiology Goes Back to School: Presenting the Face of Radiology to School Children

Meir H. Scheinfeld, MD, PhD, Carson Campe, MD, Laura L. Avery, MD

## THE PROBLEM

Among health care professionals, the critical role of radiology in patient care is obvious. For example, most emergency department patients receive some form of imaging when presenting with abdominal pain [1]. Among the general public, however, the radiologist's role is less clear. There is confusion as to the role of the radiologist, technologist, and even referring physician in image interpretation [2,3]. Furthermore, many people do not realize that radiologists are doctors [3]. The lack of general knowledge as to the importance of radiologists continues to have serious implications, particularly among policymakers [4]. One method of addressing this problem has been the ACR's Face of Radiology campaign, designed to educate the adult public that radiologists are doctors who are highly trained and experts in image interpretation [2].

## OUR SOLUTION: THE TEACHING KIT

Children can generally identify the physician roles of pediatricians and surgeons but are unable to explain what radiologists do. To address this, we decided to design and implement a preassembled radiology "teaching kit" that could be used to easily introduce our specialty to school children in a fun, exciting, and age-appropriate manner (Figure 1).

We assembled a core of interesting radiographs (normal skeletal radiographs, skeletal radiographs with fractures or dislocations, and radiographs of toys and other objects) in hard copy and electronic form, a radiology game, and a USB drive preloaded with audiovisual presentations. Users of the kit would be able to make modifications and additions to the materials to best suit their audiences, and these would also become available for others to use.

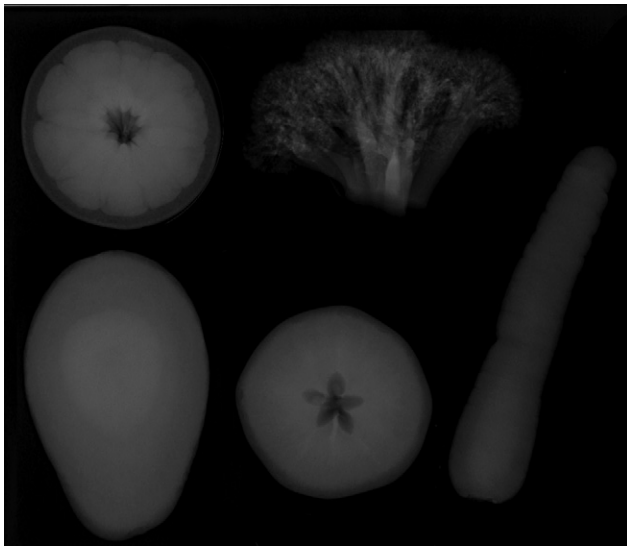
We designed materials for 2 age groups: preschool and early elementary school. For the preschool age group, we use the above materials to demonstrate what radiologists do and the different types of imaging we perform. Various items relating to health and wellness are also incorporated. In the audiovisual presentation, we use a scenario in which the class visits a hospital emergency department and "looks in" on various emergency department rooms. Radiologic images, cartoons, and cine clips are used to explain the various facets of a radiologist's job, namely, the interpretation of images, collaborating with other doctors, teaching doctors in training, performing procedures, and doing research.

For example, in the orthopedic room, we demonstrate various fractures and dislocations on radiography and allow children to make the diagnoses. In the dental room, we use orthopantomograms to demonstrate healthy dentition, cavities, the edentulous jaw, and the pediatric jaw with primary and permanent teeth. We use 3-D reconstructions of the kidneys and 4-D cardiac reconstructions to demonstrate cross-sectional imaging.

We follow this with 2 interactive games. First, we show radiographs of a range of items, including a boot, fruits, vegetables (Figure 2), and Mr. Potato Head, and allow the children to figure out what the objects are. We discuss why objects look as they do; for example, screws and batteries made from metal are whiter than the plastic parts. The second game is a skeleton assembly game in which radiographs of an



**Fig 1.** Photograph of the teaching kit demonstrating hard-film radiographs (asterisk), USB drive (black arrow), skeleton assembly game, and the portfolio case (white arrow) that holds these items.



**Fig 2.** Fruit and vegetable radiographs. Clockwise from the upper right, orange (axial view), broccoli, carrot, apple (axial view), and avocado (lateral view) are demonstrated.

entire skeleton are given to the children to assemble (Figure 3).

In our presentation to students in early elementary school (aged 7-9 years), we emphasize the radiologist's role of detecting abnormalities (which there may or may not be on any individual image) and the scientific underpinning of radiography. We stress that a radiologist is a doctor who goes to school for many years to learn the science and technical aspects of imaging as well as the medical aspects of arriving at a diagnosis.

We begin our discussion by describing the various available modalities (CT, MRI, ultrasound, etc) and explain the strengths and weaknesses of each modality for specific applications. We then focus on the science of radiography and the basics of how a radiographic image is generated. Interactive quizzes are used throughout the presentation to keep the children engaged. We use simple musculoskeletal cases to let the children "be the radiologist" and make the diagnosis, and we dem-



**Fig 3.** Photograph of children having successfully assembled a set of skeletal radiographs.

onstrate various interesting imaging artifacts and foreign bodies.

Throughout the presentation to this age group, we encourage the children to ask questions. We try to impart that radiologic imaging is a method of definitively diagnosing problems in a relatively painless manner.

## IMPLEMENTATION AND FEEDBACK

In general, the children were very interested in the presented material (Figure 3). Use of multiple instruments, such as electronic and hard copy radiographs as well as games and quizzes, kept the children's interest. Throughout the presentations, the children asked questions, with the older children asking more questions on the topic. Interestingly, the area most interesting to both age groups was the orthopantomograms. By the end of the presentation and games, the children had a new understanding of the specialty of radiology and its fundamental importance in figuring out what is wrong with a patient, "on the inside."

The availability of presentations for 2 age groups was essential. The younger age group presentation was more of a show-and-tell and interactive format, which suited this age group better. The older age group presentation was more didactic, as they were accustomed to a structured learning environment. Furthermore, for the older age group, we were able to discuss imaging appearances in more detail, for example, why a felt-tip marker is relatively lucent throughout, whereas a ballpoint pen has a metallic tip that appears white on the radiograph.

## CONCLUSIONS

Over the past year, we have successfully assembled and used a radiology teaching kit to introduce the specialty of radiology and what ra-

diologists do, to schoolchildren. We have made these presentations available to the other radiologists at our institution, who have provided positive feedback and suggestions after their presentations. Our experience suggests that the ready availability of such materials has allowed radiologists who may not have been able to collect necessary materials, to now easily be able to deliver high-quality presentations and lead interesting discussions.

Following these presentations, we gathered the impression that the children had gained an understanding of the radiologist's role in patient care. We hope that these children will convey this understanding to parents and friends, and continue to develop interest as they grow older. We would encourage others to develop such a teaching kit to help teach at an early age the importance of the specialty of radiology and the role of the radiologist.

## REFERENCES

1. Nagurney JT, Brown DF, Chang Y, Sane S, Wang AC, Weiner JB. Use of diagnostic testing in the emergency department for patients presenting with non-traumatic abdominal pain. *J Emerg Med* 2003;25:363-71.
2. Borgstede JP. It's about the patients. *J Am Coll Radiol* 2005;2:555-6.
3. Neiman HL. Face of Radiology campaign. *Acad Radiol* 2009;16:517-20.
4. Moser JW, Hastreiter DM. 2007 survey of radiologists: source of income and impact of the Deficit Reduction Act of 2005. *J Am Coll Radiol* 2009;6:408-16.

Meir H. Scheinfeld, MD, PhD, is from the Department of Radiology, Division of Emergency Radiology, Montefiore Medical Center, Bronx, New York. Carson Campe, MD, and Laura L. Avery, MD, are from the Department of Radiology, Division of Emergency Radiology, Massachusetts General Hospital, Boston, Massachusetts.

**Meir H. Scheinfeld, MD, PhD**, Montefiore Medical Center, Department of Radiology, Division of Emergency Radiology, 111 East 210th Street, Bronx, NY 10467; e-mail: [mscheinf@montefiore.org](mailto:mscheinf@montefiore.org).