



Breast Cancer Staging. Physiology Trumps Anatomy

Author: Maxine Jochelson, MD, FSBI

The purpose of this paper is to address the importance of physiologic imaging for the staging and follow up of patients with breast cancer according to the principles of precision medicine. Precision medicine is the “tailoring of medical treatment to the individual characteristics, needs and preferences of a patient during all stages of care, including prevention, diagnosis, treatment and follow-up.” Currently, physiologic imaging is primarily performed with 18F –FDG- PET/CT, but other tracers are increasingly being used towards the goal of more specific tumor targeting.

Staging

Once breast cancer is diagnosed, staging of the axilla must be performed. However, at present, imaging of the clinically negative axilla is not accurate enough to obviate histologic sampling, which is most frequently performed with sentinel lymph node biopsy. Houssami et al. reported in a meta-analysis of 31 studies that axillary ultrasound had a sensitivity of only 61.4%¹. PET/CT provides similar limited sensitivity in the general breast cancer population²; however, in patients with larger primary tumors who may undergo neoadjuvant chemotherapy, sensitivity is 82% for the detection of regional lymphadenopathy reflecting a higher likelihood of nodal metastases in women with larger cancers³. Based on these data Koolet et al recommend that all patients who will be undergoing neoadjuvant chemotherapy have an FDG PET/CT scan for locoregional staging.

Current National Comprehensive Cancer Network (NCCN) guidelines recommend against routine staging of women with Stage I or II disease and primarily recommend CT or MRI in addition to a bone scan for staging women with Stage III or IV breast cancer with the following caveat: “The use of FDG PET/CT should generally be discouraged for the evaluation of metastatic disease except in those clinical situations where other staging studies are equivocal or suspicious. Even in those situations biopsy may be more useful.” However, there are



multiple studies all demonstrating more accurate breast cancer staging with FDG PET/CT as will be briefly described below. In breast cancer detection, it is already well established that physiologic imaging of the breast (with breast MRI, Positron Emission Mammography, Molecular Breast Imaging, and Contrast Enhanced Mammography) has a higher sensitivity than purely anatomic modalities (including Full Field Digital Mammography, Digital Breast Tomosynthesis, and ultrasound).

Groheux et al. evaluated 254 women with Stage IIA through IIIC breast cancer and found that FDG PET/CT imaging changed the clinical stage in 30% of the women. Most strikingly, 21% of those women had unsuspected metastatic disease, with an upgrade rate of 10.7% in women with Stage IIB disease⁴. In a retrospective study of breast cancer patients younger than 40 years of age, Riedl et al. demonstrated a 17% upstaging rate in women with IIB disease⁵.

Every study comparing FDG PET/CT to standard imaging with CT and bone scan has demonstrated the superiority of PET/CT with accuracies of 86-90%^{6,7}. Constantinidou et al.⁸ compared FDG PET/CT to CT and bone scan and showed more disease in over 30% of patients. Although the finding of additional metastases when a patient clearly has extensive metastatic disease may not always be clinically relevant, there are times when PET/CT detects a single metastases when all other exams are negative changing treatment and prognosis. It should be stressed that in these cases biopsy confirmation is required when possible to avoid overtreatment of a false positive PET/CT finding.

Figure 1 shows PET/CT imaging of a 35-year-old Asian woman presenting with Stage IIB breast cancer who was waiting for the results of BRCA testing to determine if she were to have bilateral mastectomy and



reconstruction. PET/CT showed a 6 mm mediastinal node (normal by CT criteria) which was FDG avid. Biopsy proved metastatic disease. Treatment plan was changed from mastectomy to chemotherapy alone.

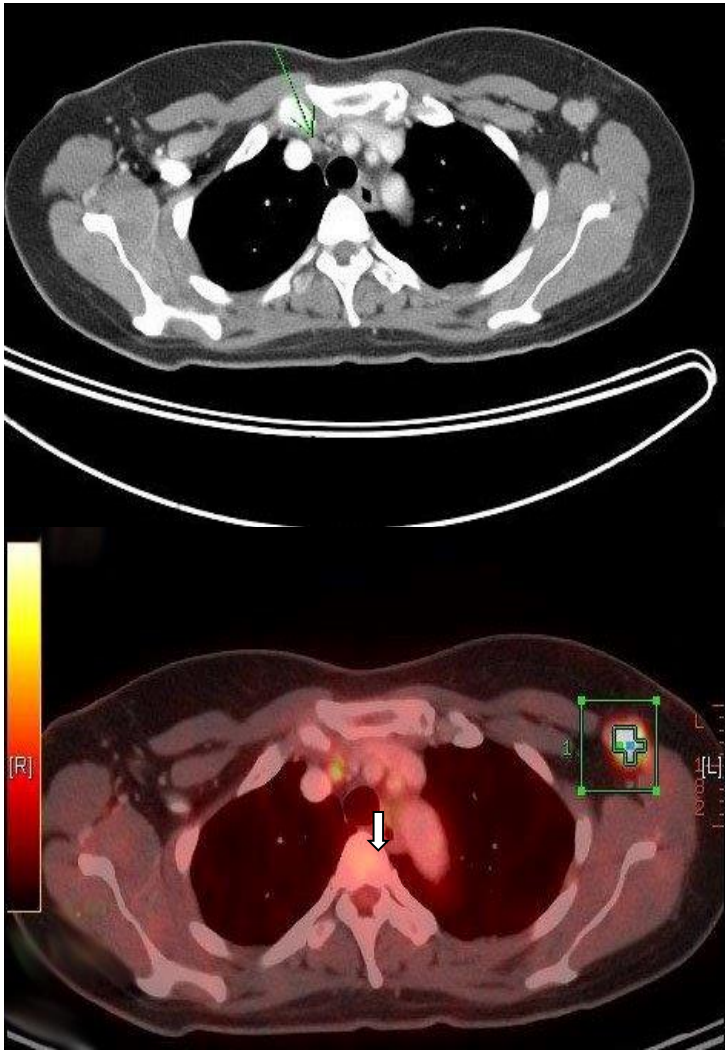


Figure 1

Despite the overall excellent results obtained with PET/CT for staging, however, its utility is not uniform among all types of breast cancer. Dashevsky et al. evaluated FDG PET/CT for its ability to detect bone metastases in 95 women with invasive lobular carcinoma (ILC). They found that ILC bone metastases were more commonly sclerotic on CT than patients with infiltrating ductal carcinoma (IDC) and infiltrating



mammary carcinoma (IMC). The standardized uptake value (SUV) max in patients with ILC was lower than in patients with IDC and in fact only 3 of 7 ILC patients with sclerotic bone metastases had a FDG-positive PET scan⁹. In another study, Hogan et al. evaluated 87 patients with ILC and found that PET/CT did not reveal unsuspected extra-axillary nodes in any patient¹⁰.

Follow up

1. Treatment Response

Besides being the most accurate modality for locoregional and systemic staging in breast cancer, 18 F-FDG PET/CT accurately predicts treatment response. As far back as 1993, Wahl et al. reported that patients who ultimately responded to chemotherapy showed a 50% decrease in uptake two months into chemotherapy compared to nonresponders, and this change in uptake was independent of change in size¹¹. Vranjesevic et al. compared the predictive ability of PET/CT to that of conventional imaging in 61 patients and showed that the positive predictive value (PPV) of PET/CT was 93% compared to 85% for conventional imaging, and that the negative predictive value (NPV) was 84% for PET/CT compared to 59% for conventional imaging¹². Other (non-FDA approved) PET tracers have also been demonstrated to predict response at an early time point, allowing for potential earlier treatment change (risk adaptive treatment). Kenny et al. used 18F-fluorothymidine (FLT) PET which assesses tumor proliferation and showed that a decrease in SUV at 1 week discriminated between clinical response and stable disease¹³. Theoretically, if the oncologists can determine that a certain drug combination is not working at an earlier time point, the treatment course may be altered and the patient could benefit from a different treatment before an increase in disease burden which may render the disease



more difficult to treat, and avoid unnecessary morbidity of ineffectual therapy. This “risk adaptive” approach has been successful in treating patients with lymphoma and hopefully can be adopted in breast cancer as well. Once a patient has been treated for breast cancer, accurate assessment of treatment response is vital for both clinical trials as well as for patient care. Currently, for clinical trials and in many practices, follow up assessments of patients are often made using purely anatomic imaging, most often with CT scanning.

Decrease in the size of the tumor after treatment is the measure of response. This approach is particularly problematic in women with breast cancer since bone is the most common site of metastatic disease and bone metastases cannot be reliably measured unless there is an extraosseous soft tissue mass associated with the bone lesion. Otherwise, it is difficult to determine treatment response. Development of or increase in sclerosis can be due to either healing or progressive disease. Likewise, a bone scan may show increased uptake caused by a metabolic flare, progression, or disease healing.

If PET/CT is employed, physicians will be able to measure the change in SUV reflecting change in metabolic activity and thus determine response to treatment.

Figure 2 shows PET/CT imaging in a patient with known hypermetabolic sclerotic metastasis to L3. After treatment, there were no changes in the appearance on CT imaging; the patient would be considered as having a stable disease. However, on PET/CT imaging, there is a significant reduction in FDG activity, confirming treatment response.

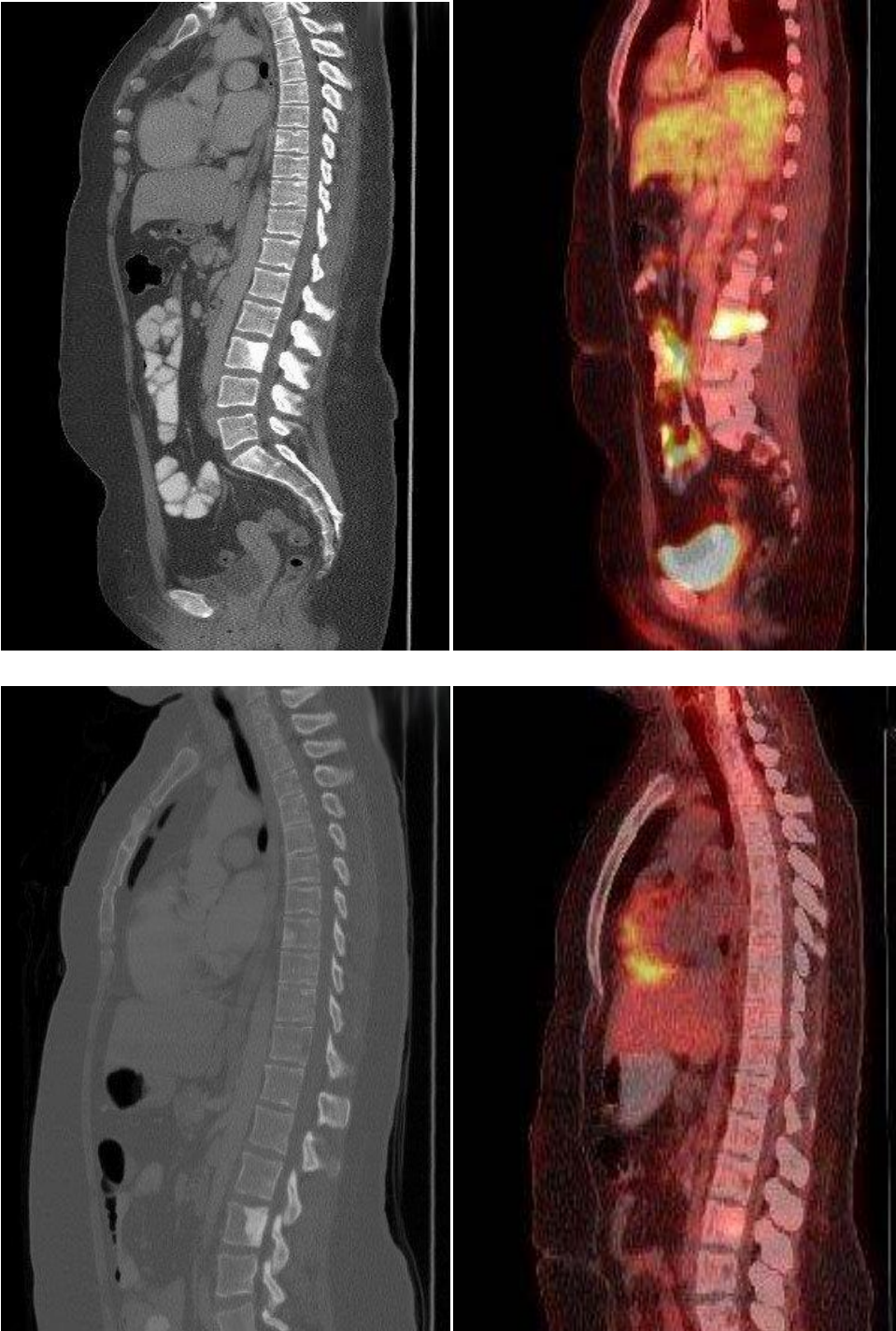


Figure 2



Figure 3 shows PET/CT imaging in a patient with bone only metastases at presentation and who had a good response to chemotherapy in her bone metastases. However, at the same time as the response in the bone, the patient developed a liver metastasis, which was only seen on FDG PET/CT.

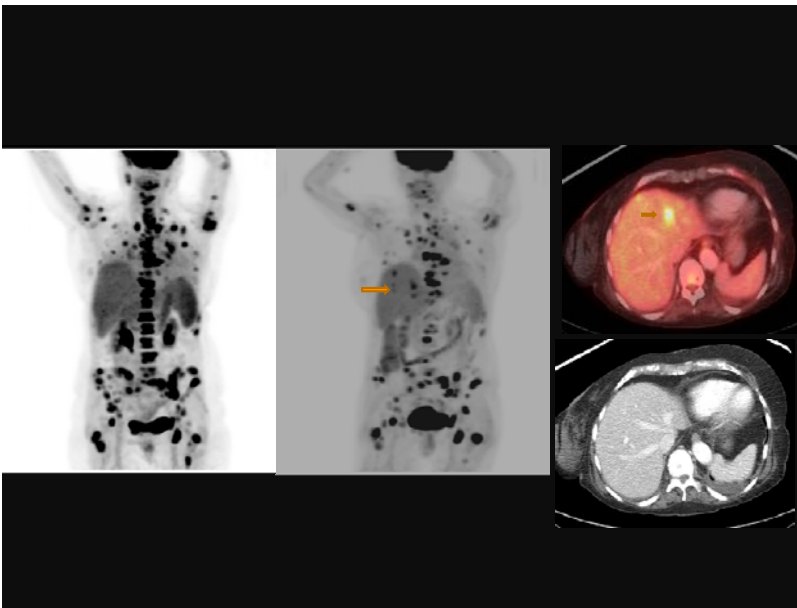


Figure 3

Another source of difficulty when assessing treatment response is that patients often have a heterogeneous response within the various tumor sites. This is of particular concern in women presenting with bone metastases. It is well recognized that even within the same patient, there is tumor heterogeneity¹⁴. Huyge et al. demonstrated that in 46 women with bone dominant metastatic breast cancer, the women had heterogeneous response in 43% of the treatment phases; in the subset with both bone and extra-bone metastases, PET/CT showed discordant responses between bone and extra-bone metastases in 30% of treatment phases.¹⁵ In a



study that did not include FDG PET Lorincz¹⁶ evaluated 48 women with metastatic breast cancer and showed that half of those with HER 2+ disease lost the genotype in their bone metastases.

2. Clinical trial evaluation

The treatment response of patients in clinical trials is most often evaluated by CT using the RECIST (Response Evaluation Criteria in Solid Tumors) 1.1 criteria and is therefore purely anatomic. Five lesions are chosen per patient and except for lymph nodes, a single measurement of the longest diameter of the metastasis is followed. For lymph nodes, a measurement of the short axis, which must be at least 1.5 cm, is followed. Reliability of measurements has been called into question. PERCIST (Positron Emission Tomography Response Criteria in Solid Tumors) adds physiology to anatomy. FDG PET/CT is performed >10 days after chemotherapy with measurement of up to five lesions with the most intense uptake. Response is defined as the % change in SUL (SUV corrected for lean body mass).

The following case demonstrates the superiority of PERSIST:

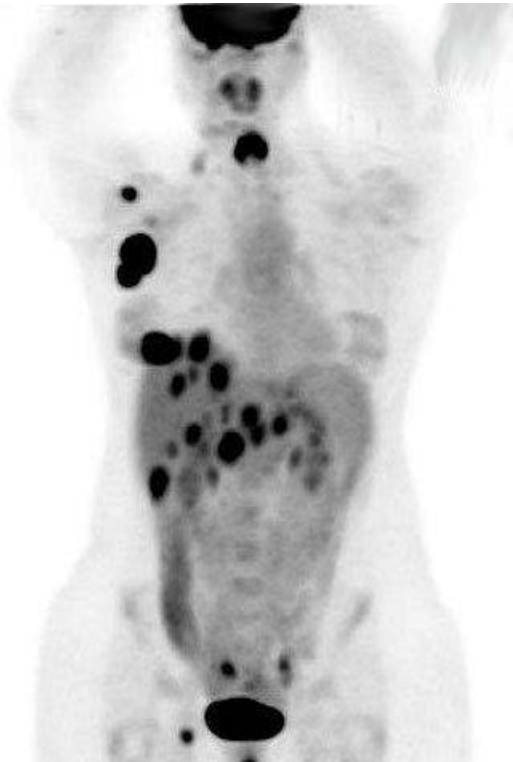
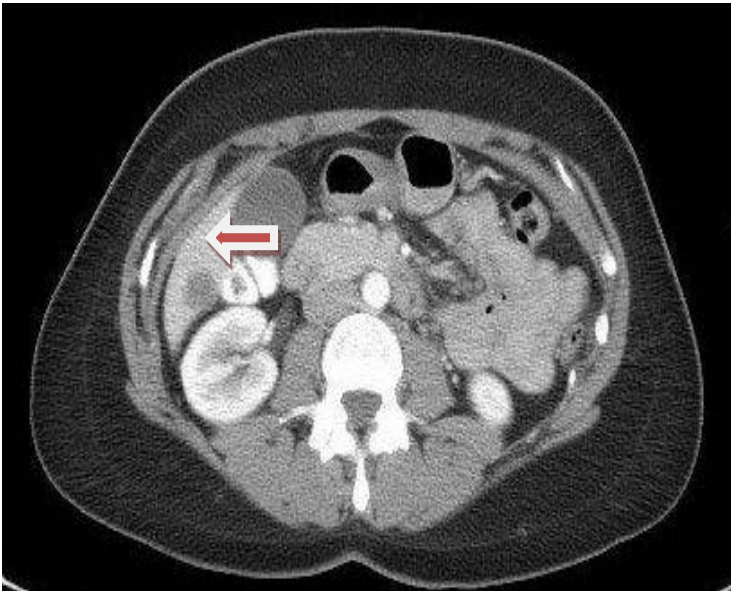
Figure 4 shows FDG PET/CT in a 35-year-old woman who presented with lung and liver metastases. As a baseline (Figure 4A) for a clinical trial, she had CT chest, abdomen, and pelvis with contrast as required by protocol which used RECIST 1.1 criteria to assess response. She also had a PET/CT. After the first 3 months of chemotherapy she was re-imaged (4B) as per protocol and demonstrated complete response in the lung and near complete response in the liver on both CT and PET/CT with a residual small, mildly FDG avid lesion in the posterior right lobe. She therefore qualified for more chemotherapy after which CT was stable by RECIST



which meant that she would undergo another 2 cycles of chemotherapy even though the residual liver lesion had become more hypermetabolic and a new area of FDG avidity had developed in another part of the liver. After the next 2 cycles of this experimental regimen which was clearly not working by PET criteria, she also demonstrated progression on CT. At that point she was considered to have disease progression and taken off the initial protocol and switched to a different chemotherapy combination:

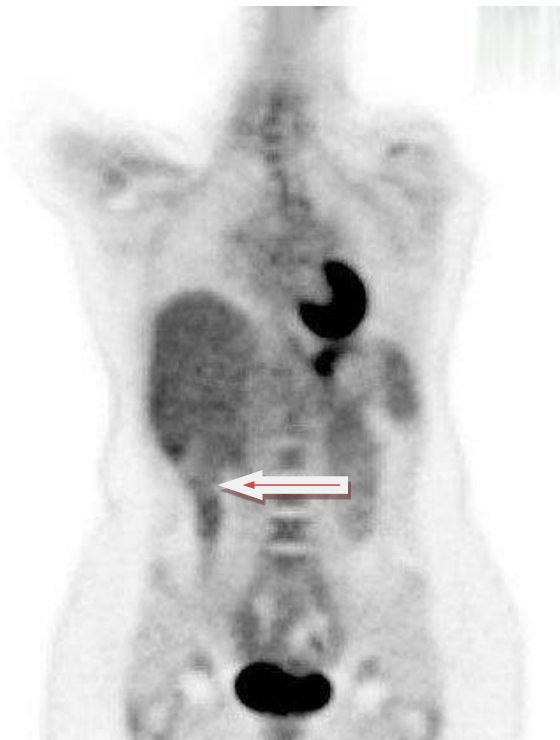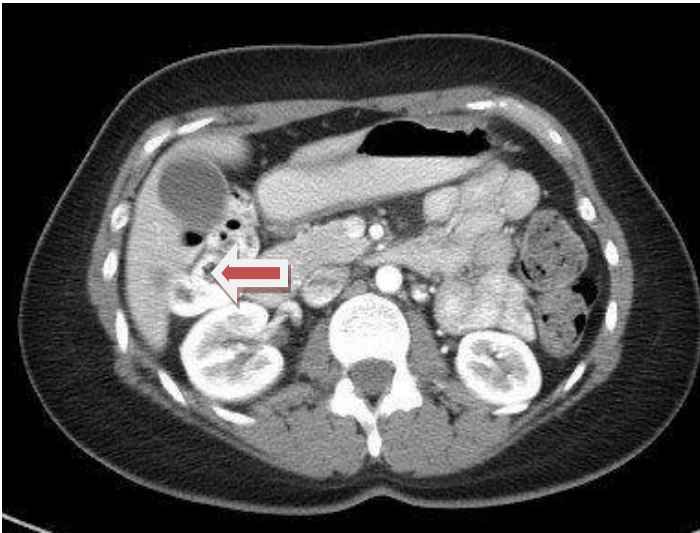


4A



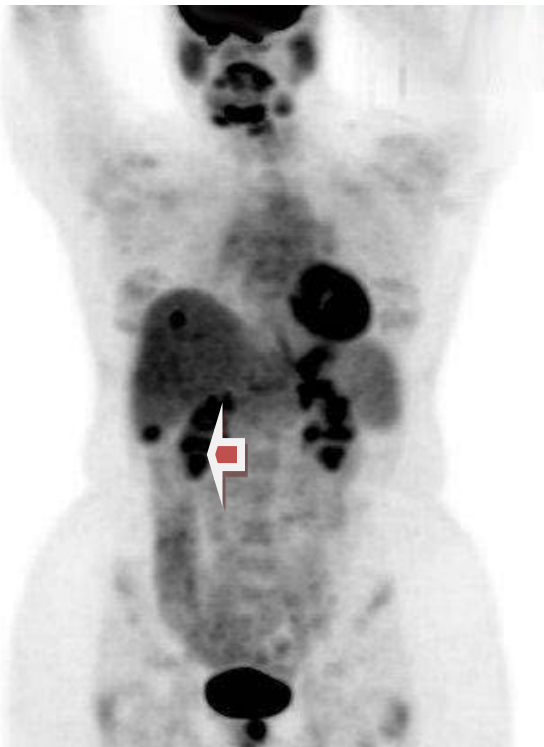
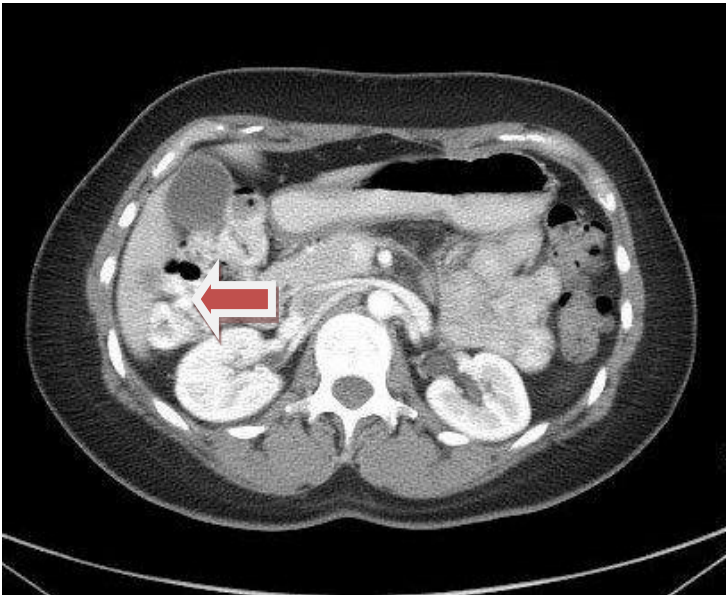


4B



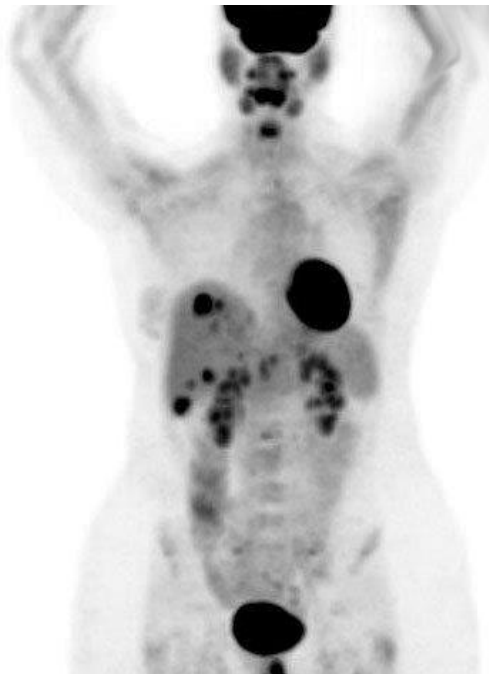
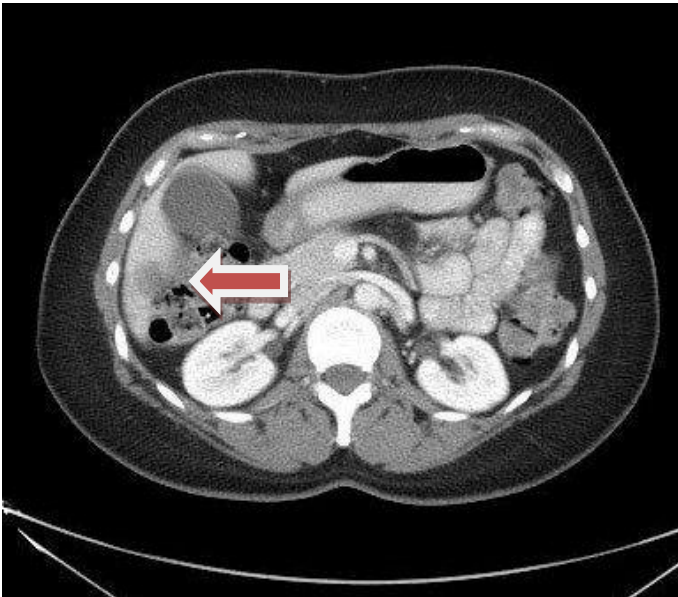


4C





4D





There are several reasons why this case is an important example. To begin with, this patient underwent two additional cycles of chemotherapy that was not working. This is not only burdensome for the patient; these drugs can be very expensive--far more costly than the additional cost of a PET scan, and can result in additional side effects. Additionally, since this was done on a clinical trial which evaluated the ability of the drug to improve freedom from progression--an endpoint measured in weeks or months in patients with metastatic breast cancer--the results demonstrated 2 additional months of freedom from progression by using the CT results which suggested that the chemotherapy regimen being tested had performed better than it actually had, instead of the more accurate PET/CT results which indicated its lack of efficacy.

In a retrospective study, Riedl et al. compared RECIST to PERSIST for their ability to predict progression free survival (PFS) and disease specific survival (DSS) in 71 stage IV patients. PET demonstrated response in patients who had stable CTs and was significantly better at predicting PFS and DSS in these patients¹⁷.

Looking forward

Targeted therapy is increasingly being used for various subtypes of breast cancer. At the same time, tumor-specific tracers are being developed including ¹⁸F-fluoroestradiol (FES) which targets estradiol and may be superior in some estrogen receptor positive tumors¹⁸ and ⁸⁹Zr-trastuzumab which targets HER 2+ cancers. Although discussion of these tracers is beyond the scope of this paper, it should be noted that the use of new and different tracers should enhance the ability to stage cancer, predict for and assess treatment response beyond the standard imaging with -FDG PET/CT.



Conclusion

In conclusion, physiologic imaging trumps anatomic imaging not only in the detection of breast cancer but also in the staging of breast cancer and evaluation of response to treatment. As we aim to develop more successful and targeted personalized treatment, targeted personalized imaging will play a critical role in optimizing patient care as well as clinical trial evaluation.



References

1. Houssami N, Ciatto S, Turner RM, Cody HS, 3rd, Macaskill P. Preoperative ultrasound-guided needle biopsy of axillary nodes in invasive breast cancer: meta-analysis of its accuracy and utility in staging the axilla. *Annals of surgery*. Aug 2011;254(2):243-251.
2. Heusner TA, Kuemmel S, Hahn S, et al. Diagnostic value of full-dose FDG PET/CT for axillary lymph node staging in breast cancer patients. *European journal of nuclear medicine and molecular imaging*. Oct 2009;36(10):1543-1550.
3. Koolen BB, Vrancken Peeters MJ, Aukema TS, et al. 18F-FDG PET/CT as a staging procedure in primary stage II and III breast cancer: comparison with conventional imaging techniques. *Breast cancer research and treatment*. Jan 2012;131(1):117-126.
4. Groheux D, Hindie E, Delord M, et al. Prognostic impact of (18)FDG-PET-CT findings in clinical stage III and IIB breast cancer. *Journal of the National Cancer Institute*. Dec 19 2012;104(24):1879-1887.
5. Riedl CC, Slobod E, Jochelson M, et al. Retrospective analysis of 18F-FDG PET/CT for staging asymptomatic breast cancer patients younger than 40 years. *Journal of nuclear medicine : official publication, Society of Nuclear Medicine*. Oct 2014;55(10):1578-1583.
6. Tatsumi M, Cohade C, Mourtzikos KA, Fishman EK, Wahl RL. Initial experience with FDG-PET/CT in the evaluation of breast cancer. *European journal of nuclear medicine and molecular imaging*. Mar 2006;33(3):254-262.
7. Fuster D, Duch J, Paredes P, et al. Preoperative staging of large primary breast cancer with [18F]fluorodeoxyglucose positron emission tomography/computed tomography compared with conventional imaging procedures. *Journal of clinical oncology : official journal of the American Society of Clinical Oncology*. Oct 10 2008;26(29):4746-4751.
8. Constantinidou A, Martin A, Sharma B, Johnston SR. Positron emission tomography/computed tomography in the management of recurrent/metastatic breast cancer: a large retrospective study from the Royal Marsden Hospital. *Annals of oncology : official journal of the European Society for Medical Oncology / ESMO*. Feb 2011;22(2):307-314.
9. Dashevsky BZ, Goldman DA, Parsons M, et al. Appearance of untreated bone metastases from breast cancer on FDG PET/CT: importance of histologic subtype. *European journal of nuclear medicine and molecular imaging*. Oct 2015;42(11):1666-1673.
10. Hogan MP, Goldman DA, Dashevsky B, et al. Comparison of 18F-FDG PET/CT for Systemic Staging of Newly Diagnosed Invasive Lobular Carcinoma Versus Invasive Ductal Carcinoma. *Journal of nuclear medicine : official publication, Society of Nuclear Medicine*. Nov 2015;56(11):1674-1680.
11. Wahl RL, Zasadny K, Helvie M, Hutchins GD, Weber B, Cody R. Metabolic monitoring of breast cancer chemohormonotherapy using positron emission tomography: initial evaluation. *Journal of clinical oncology : official journal of the American Society of Clinical Oncology*. Nov 1993;11(11):2101-2111.



12. Vranjesevic D, Filmont JE, Meta J, et al. Whole-body (18)F-FDG PET and conventional imaging for predicting outcome in previously treated breast cancer patients. *Journal of nuclear medicine : official publication, Society of Nuclear Medicine*. Mar 2002;43(3):325-329.
13. Kenny L, Coombes RC, Vigushin DM, Al-Nahhas A, Shousha S, Aboagye EO. Imaging early changes in proliferation at 1 week post chemotherapy: a pilot study in breast cancer patients with 3'-deoxy-3'-[18F]fluorothymidine positron emission tomography. *European journal of nuclear medicine and molecular imaging*. Sep 2007;34(9):1339-1347.
14. Gerlinger M, Rowan AJ, Horswell S, et al. Intratumor heterogeneity and branched evolution revealed by multiregion sequencing. *The New England journal of medicine*. Mar 8 2012;366(10):883-892.
15. Huyge V, Garcia C, Alexiou J, et al. Heterogeneity of metabolic response to systemic therapy in metastatic breast cancer patients. *Clinical oncology*. Dec 2010;22(10):818-827.
16. Lorincz T, Toth J, Badalian G, Timar J, Szendroi M. HER-2/neu genotype of breast cancer may change in bone metastasis. *Pathology oncology research : POR*. 2006;12(3):149-152.
17. Riedl CC. American Society of Clinical Oncology; 2015; Chicago.
18. Dehdashti F, Mortimer JE, Trinkaus K, et al. PET-based estradiol challenge as a predictive biomarker of response to endocrine therapy in women with estrogen-receptor-positive breast cancer. *Breast cancer research and treatment*. Feb 2009;113(3):509-517.