

AAID NEWS



3D Printing: A New Dimension of Implant Dentistry



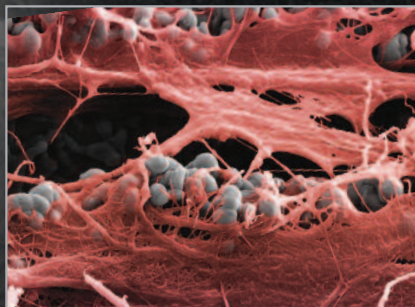
INSIDE

- Lights, Camera, Action!
- 24-Hour Teeth
- It's All About the Patient

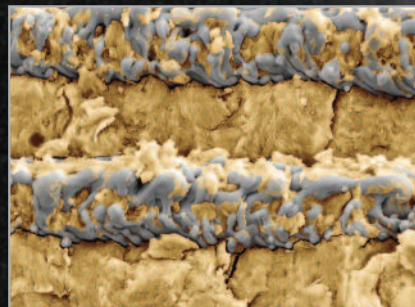
better science, better implants

is osseointegration enough?

Only the Laser-Lok surface has been shown using light microscopy, polarized light microscopy and scanning electron microscopy to also be effective for soft tissue attachment.^{1,2}




Colorized SEM shows connective tissue physically attached to the Laser-Lok surface.¹



Colorized SEM of Laser-Lok[®] microchannels shows superior osseointegration³

interact at
laser-lok.com

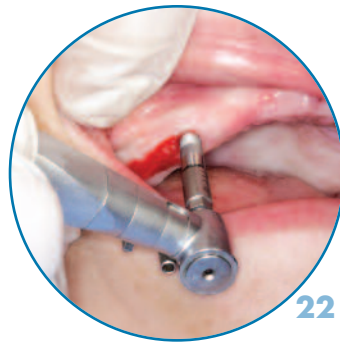
1. Human Histologic Evidence of a Connective Tissue Attachment to a Dental Implant. M Nevins, ML Nevins, M Camelo, JL Boyesen, DM Kim. International Journal of Periodontics & Restorative Dentistry. Vol. 28, No. 2, 2008. 2. Histologic evidence of a connective tissue attachment to laser microgrooved abutments: a canine study. M Nevins, DDS, DM Kim, DDS, DMSc, SH Jun, DDS, MS, K Guze, DMD, P Schupbach, PhD, ML Nevins, DMD, MMSc. Accepted for publication: IJPRD, Vol 30, No. 3, 2010. 3. Maintaining inter-implant crestal bone height via a combined platform-switched, Laser-Lok[®] implant/abutment system: A proof-of-principle canine study. M Nevins, ML Nevins, L Gobbato, HJ Lee, CW Wang, DM Kim. Int J Periodontics Restorative Dent. Volume 33, Number 3, 2013. SPMP17297 REV A OCT 2017



12



18



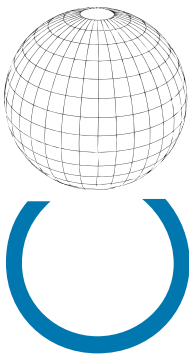
22



50



contents



aaid.com

PUBLISHED BY THE AMERICAN ACADEMY OF IMPLANT DENTISTRY / WINTER 2018

Lead Stories

- 4 Editor's Notebook
Creative Destruction
- 8 Industry News
- 12 COVER STORY
3D Printing: A New Dimension of Implant Dentistry
- 18 Business Bite
Lights, Camera, Action!
- 20 Legal Bite
The Changing Legal Horizon
- 22 Clinical Bite
24-Hour Teeth
- 26 Clinical Bite
American Academy of Implant Dentistry selects ePoster and Table Clinic Winners
- 28 JOI Sampler

AAID News

- 32 President's Message
"It's All About the Patient"
- 36 Then and Now
How Times Have Changed
- 38 Featured MaxiCourse®
Washington D.C. (Mid-Atlantic) MaxiCourse®
- 40 Academy News
- 45 AAID Very Visible at GNYDM
- 46 Annual AAID Business Meeting Summary
- 48 Focus on the Sinus 2.0
- 50 Dental Implant World Joined the AAID in San Diego
- 52 Down Syndrome Doesn't Keep Andrew Down
- 54 2017 AAID Associate Fellows
- 61 2017 AAID Fellows
- 64 New Members
- 66 Continuing Education Bite
- 70 Ad Index



By James E. Ference,
DMD, MBA, AFAAID, DABOI/ID
Editor, AAID News

"Creative Destruction"

Check out our feature article on 3D printing starting on page 12. This relatively new technology is transforming many areas including dentistry. While printing with a resin is probably the most known variation, other systems will be developing soon. During a visit to a leading dental laboratory not long ago, the research and development staff described their interest in producing all metal crowns not by the traditional casting process, but by using a 3D printer that sprays a metal particulate that is simultaneously "welded" by using a precise laser.

The economist Joseph Schumpeter, in 1942, described the process of dynamic economic growth as "creative destruction." It is disruptive and a source of great pain for those whose talent or tools are being outdated by new technology. To survive and prosper, one must not fight the tidal changes leading to better and more efficient technologies. We must accept the fact that part of our skill set will be anti-

quated by new ideas and machines, and must be replaced if, in fact, a better way evolves. Even the highly trained cardiovascular surgeon has seen part of his market demand diminish due to the development of stenting techniques.

So too, most of what we do today will probably fade into obsolescence as the years go by. It is not easy to accept, but we must honestly and fearlessly measure new ideas. That way we can decide if they represent

real enhancements that should lead to throwing aside our current ways, or are merely over-hyped marketing efforts that steal attention from legitimate improvements.

For those pioneers willing to blaze the newest trail, risk is part of the equation by which they live. But for many practitioners, a slightly more restrained approach could be summed up well by the Alexander Pope quotation, "Be not the first by whom the new are tried, nor yet the last to lay the old aside."

For those involved in the challenging field of oral implantology, the AAID, through its training programs and various forums, is perhaps the best vehicle available to the clinician to help find and evaluate changing technology to evaluate whether it is really better scientifically and economically. ●

We must accept the fact that part of our skill set will be antiquated by new ideas and machines, and must be replaced...

Do YOU have ideas, strategies, comments, or observations that you want to share with your colleagues? Send them to me at editor@aaid.com.

ARE YOU MAKING THE MOST of YOUR MEMBERSHIP?



Obtain the best education through AAID's comprehensive dental implant education

- ✓ AAID Annual Conference
- ✓ District Meetings
- ✓ NEW! AAID Online Clinical Classroom
- ✓ MaxiCourses®
- ✓ Live Learning Center, online education
- ✓ Webinars

Keep up on the latest news, research, and techniques through AAID publications

- ✓ *Journal of Oral Implantology*, the AAID's official scientific journal—cutting edge research and clinical applications
- ✓ *AAID News*, a quarterly newsletter featuring clinical, business, legal and industry information
- ✓ *Clinical Video Bite*, a monthly email with a full-length recorded lecture, as well as access to the archives
- ✓ *Implant Insight*, a weekly electronic newsletter from the AAID features the top news articles that your patients will be asking you about

Improve the business of your practice

- ✓ Member Advantage Program saves you money with companies you already use.
- ✓ *Business Bite*, a monthly electronic newsletter from the AAID providing implant dentists with practice management information, insights and tips
- ✓ Leverage the power of the AAID for exclusive rates on Treloar & Heisel Insurance programs
- ✓ Legal forms to personalize and use in your practice

Educate patients about dental implants

- ✓ Animated videos to educate your patients on dental implant procedures and post-op care
- ✓ Patient Education Brochures – download FREE print-ready files of our three brand-new brochures, or order personalized copies.
- ✓ Implant Identification Card —record information for patients about the implants used in their treatment

Distinguish yourself by earning bona fide credentials in implant dentistry recognized by US court decisions

- ✓ Associate Fellow
- ✓ Fellow

Develop relationships with other dentists active in dental implants

- ✓ Annual Conference—meet with over 1,000 fellow dental professionals and learn from experts from throughout the world
- ✓ District Meetings—convenient locations and the chance to meet with peers in a relaxed atmosphere
- ✓ A searchable online directory to keep you in touch with your colleagues



AMERICAN ACADEMY
OF IMPLANT DENTISTRY

For more information contact the AAID:

211 East Chicago Avenue, Suite 750, Chicago, Illinois 60611
312.335.1550 (ph) 312.335.9090 (fax) info@aaid.com
www.aaid.com

Special USA Visit- Learn from the Inventor of PRF • Joseph Choukroun
Seattle March 16, 2018 • Limited Seating Reserve Now

PROCESS FOR PRF™
CHOUKROUN PRF™ SYSTEM



Cost-effective and natural ways to regenerate tissues

- Save money for your practice and begin using natural PRF in everyday practice as predictable barrier membranes, plugs for extraction sockets, and gingival grafts in periodontology
- Accelerates wound healing
- Improves bone graft stability
- Experience extensive hands-on practice performing phlebotomy techniques
- Learn an inexpensive, scientifically proven method to enhance patients' hard and soft tissue healing through the use of a simple centrifuge
- Predictable soft tissue regeneration

Learn More About the Benefits of PRF with our 1 Day Courses

For information and reservations go to www.hitecimplantsusa.com or call 800-452-0582

2018 One Day Seminars

- | | | |
|------------------------|----------------------|------------------------|
| Los Angeles Sat Jan 27 | Santa Ana Sat May 19 | San Antonio Fri Oct 26 |
| Boston Sat Feb 10 | Seattle Sat June 9 | Dallas Sat Oct 27 |
| Phoenix Fri May 18 | Chicago Sat Oct 13 | |

DUO Quattro Centrifuge:

Don't You and Your Patients Deserve Choukroun's Process PRF?



The Choukroun Difference

	Choukroun PRF	Other Companies
Inventor of PRF	YES	NO
18 Years of On-Going Research	YES	NO
World-Wide Distribution of Product and Lectures	YES	NO
Continuous Modification of Techniques based on 1,000s of Clinical Case Reviews and Research	YES	NO
Continuous Review and Modifications of Centrifuge and Blood Collection Tubes	YES	NO
On-Going Updates of How and Where to Use Liquid PRF and PRF Membranes based on clinical Reviews and Research Available to Process for PRF Customers	YES	NO

Cortical Cancellous Mineralized Bone



250-1000 Microns

Size	Your Price
0.5cc	\$40.00
1.0cc	\$56.00
2.5cc	\$83.00

Buy 5 Get 1 FREE!

No Dealers Pricing Expires 2/28/2018

Neomem FlexPlus Native Porcine Peritoneum - Strong performance with a supple touch.

Stronger- Neomem® FlexPlus has 3 times the suture pull out strength compared to Bio-Gide and resorption time of 3-4 months.

Supple- Lack of memory means that Neomem® FlexPlus drapes and conforms to the defect site.

Better Initial Resorption Rate- Compared to Bio-Gide®, Neomem® FlexPlus initial in-vivo resorption profile suggests that Neomem® FlexPlus is more stable.

Less Inflammation- In-vivo testing also demonstrates that Neomem® FlexPlus produced a lower level of early inflammation than Bio-Gide® and Neomem® FlexPlus shows a lower level of a giant cell response.

Advantages

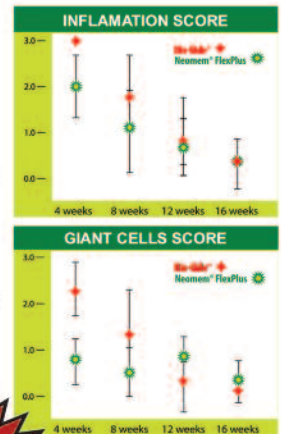
- High suture pull out strength
- Excellent draping
- Lower inflammation
- 3-4 month resorption
- Easy handling

Neomem Flex Plus

- 15 x 20 mm \$92
- 20 x 30 mm \$115
- 30 x 40 mm \$165

Buy 5 Get 1 FREE!

No Dealers - Pricing Expires 2/28/2018



*Published in Science, Technology, Innovation, Feb. 1-5, 2015. All trademarks are the property of their respective owners.



Dental Implant
TECHNOLOGIES

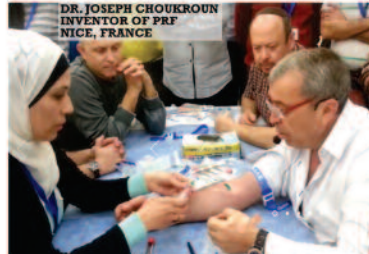See Us in L.A.
 Feb. 28 - March 3
Academy of Osseointegration
Booth 832

www.hitecimplantsusa.com • 800-452-0582 • usaimplants@gmail.com

PROCESS FOR PRF™

CHOUKROUN PRF™ SYSTEM

Dr. Joseph Choukroun to Instruct



**Learn from the
Inventor of PRF!**
Special Seattle Course
March 16th
Limited Seating • Reserve Now



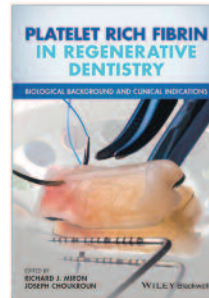
Dr. Choukroun Soft Brushing Kit

\$550.00
SKU#ST-UP

This kit was designed by Dr. Joseph Choukroun to extend the flap without the need for incision. The concept of this product is to disorganize the collagen fibers of the fibrous periosteum. This reduces the stiffness of the flap allowing the flap to release farther. This kit does not cut anything at all. The flap is released as a result of the separation of the periosteum fibers.

Kit Includes 5 Instruments:

- Regular Tip
- Angulated Right Tip (Posterior)
- Medium Tip
- Angulated Left Tip (Posterior)
- Large Tip



Platelet Rich Fibrin in Regenerative Dentistry

Biological Background and
Clinical Indications

\$110.00

The first book devoted exclusively to the subject,
Platelet Rich Fibrin in Regenerative Dentistry

Platelet Rich Fibrin in Regenerative Dentistry offers comprehensive, evidence-based coverage of the biological basis and clinical applications of PRF in dentistry. Co-edited by a leading researcher in tissue regeneration and the inventor of the PRF technique, it brings together original contributions from expert international researchers and clinicians.

Increase your Implant Practice with PRF and Sinus Augmentation • March 17 in Seattle

Learn Basic Sinus Surgery Techniques • Lectures and Live Surgery
by Dr. Le Roy Horton and Dr. Steven Paige

Limited Registration • Reserve Now!



Dental Implant
TECHNOLOGIES

www.hitecimplantsusa.com • 800-452-0582 • usaimplants@gmail.com

- Choukroun Special
Seattle Course
March 16
- Sinus Surgery
Techniques
March 17

Glidewell Dental Announces Distribution of Align Technology's iTero Element® Scanner with glidewell.io™ In-Office Solution

Glidewell Dental announced an agreement with Align Technology, Inc. to distribute the iTero Element® intraoral scanning system in North America with the newly unveiled glidewell.io™ In-Office Solution, a chairside restorative ecosystem set to simplify the process of prescribing and delivering laboratory-quality dental restorations.

The glidewell.io Solution will provide a streamlined workflow with Align's iTero Element scanner and Glidewell's fastdesign.io™

Software. Final designs can be used to prescribe a laboratory restoration or sent to the fastmill.io™ In-Office Unit for immediate chairside milling.

844.949.7184

invisalign.com

www.glidewell.io

itero.com



Hybridge XD Cuts Chair Time Dramatically

Fourth quarter 2017 Hybridge CE courses reached sell-out capacity as its founder, Frank R. LaMar, DDS, onboarded new waves of doctors on Hybridge's latest, patent-pending, digital full-arch protocol, Hybridge XD.

HYBRIDGE XD

EXPRESS DIGITAL

This cutting-edge process provides practitioners the ability to deliver a high-quality, definitive full-arch prosthesis in just four hours of doctor time and three appointments. The 100+ doctors trained in Hybridge XD to date benefit from a 43% reduction in chair time as compared to Hybridge's traditional full-arch protocols. With Hybridge XD, doctors increase their productivity, profitability and drive increased case conversion. Patients benefit from increased immediacy, without sacrificing safety, quality or esthetics.

585.319.5400

HybridgeNetwork.com/XD

Gilleard Dental Marketing Expands Custom Magazine Direct Mail Program

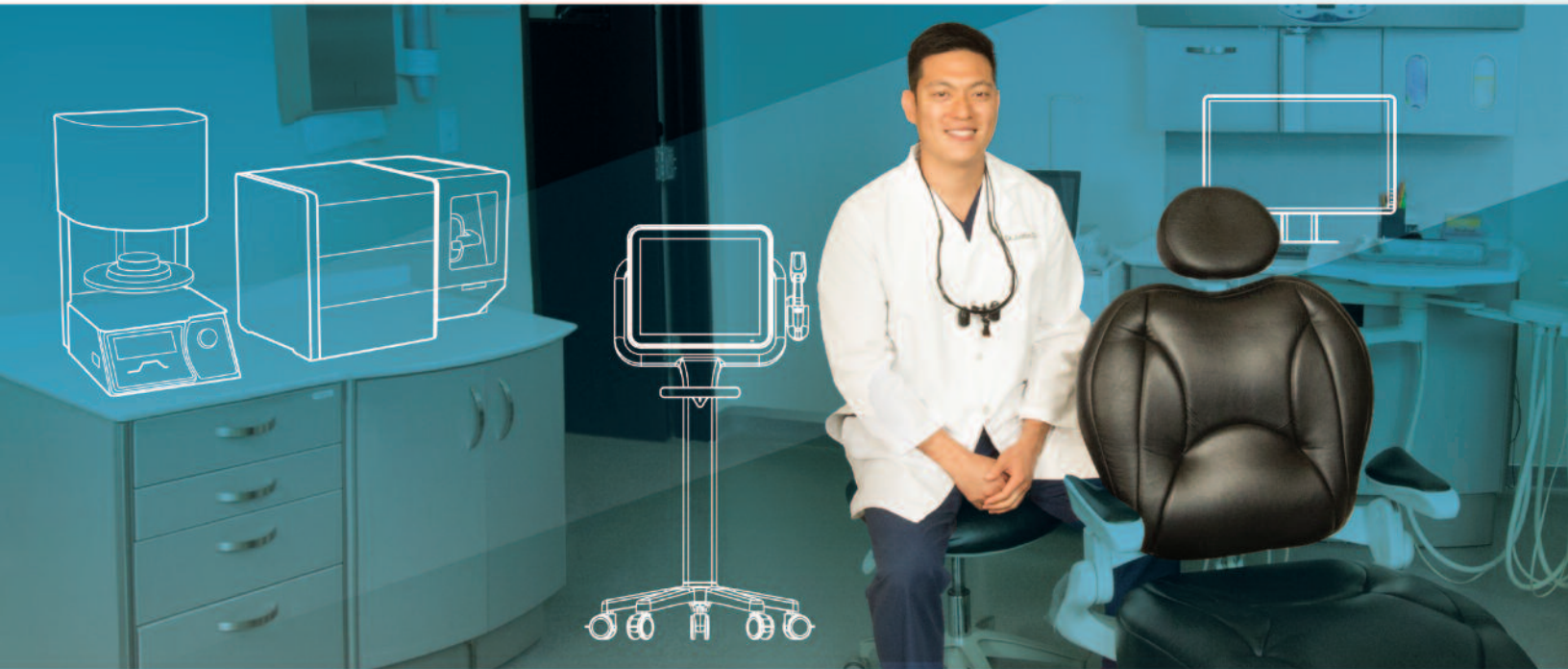As more dentists offer full-service dental implants, the marketing arena for implants becomes more competitive. One of the main marketing vehicles, the Internet, has become overly populated with implant advertising.

As an adjunct or replacement for competitive Internet marketing of dental implants, Gilleard Dental Marketing developed an affordable, targeted direct mail program: their Custom Magazine Direct Mail program. These 12- and 16-page magazines are full of photos, imagery, messaging and call-to-actions, based on market research for implant dentists in general and each individual's practice specifically.



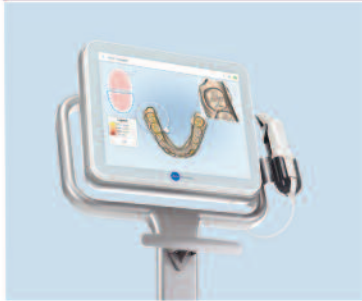855.486.2410

GilleardDentalMarketing.com



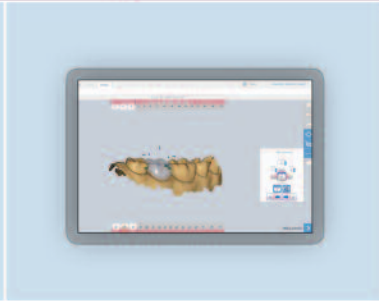The glidewell.io™ In-Office Solution is the simplest way to prescribe and deliver dental restorations, powered by the world's most innovative dental laboratory. This digital ecosystem empowers clinicians with an intuitive interface from which you can create in-office restorations, collaborate with Glidewell Laboratories and find on-demand support.

The glidewell.io Suite of Technologies



iTero Element® Intraoral Scanner

The iTero Element® Intraoral Scanner from Align Technology, Inc., delivers a quick, intuitive scanning experience that generates high-precision results.



fastdesign.io™ Software

The fastdesign.io™ Software enables you to design restorations, prescribe cases through Glidewell Laboratories, and find on-demand support from a single interface.



fastmill.io™ In-Office Unit

Create in-office restorations from BruxZir® NOW zirconia, Obsidian® lithium silicate, CAMouflage® NOW Nanohybrid Composite and BioTemps® NOW PMMA.



finalstage.io™ Ceramic Oven

An optional component of the glidewell.io Solution, the finalstage.io™ Ceramic Oven gives you the power to crystallize and characterize lithium silicate ceramic restorations.

iTero Element is a registered trademark of Align Technology, Inc.

NOW STREAMING



Listen and Subscribe:



iTunes



Google Play



STITCHER

The Academy aims to foster informal discussions about the world of implant dentistry, mirroring the collaborative spirit of our members in our podcast.

Hosted by **Dr. Daniel Domingue** and **Dr. Justin Moody**, the podcast explores topics and issues encompassed in the implant practitioner's world.



Daniel Domingue, DDS, FAAID, DABOI



Justin Moody, DDS, FAAID, DABOI

Visit aaidpodcast.com to learn more and listen now



Reasonably Priced for over 36 years.



Fully Assembled Integrity Tapered Implant



HT 30 Thumb Drive

Retention Screw



Integrity Zest Locators

Available in all diameters



Ball Post Abutments

Available in all diameters



Ti Bases

Available in sizes 3.7 through 8.0 mm



Platform Switch Abutments

Available in angles 0°, 15° & 30°



Stock Abutments

Available in angles 0° & 15°

- Our unique tapered design is anatomically correct, enabling easier implant placement, while providing enhanced primary stability.
- Designed to be a single surgery implant, that preserves both crestal bone, and soft tissue.
- Simple abutment placement due to the soft tissue level connection.
- Internal pentagon offers 5 secure, and positive abutment positions.
- Strong, stable, and retrievable abutment design utilizing large retention screws (2.0mm and 2.5mm).
- Internal tapered abutment connection to reduce the abutment/screw load.
- A lab "Friendly" system throughout the world.

Designed for Simplicity, Engineered for Strength.

Tatum Integrity Implants feature an internal pentagon offering 5 secure, and positive abutment positions.



Experience you can trust.

The combination of strength, reliability, 36 years of clinical service and reasonable pricing makes buying Tatum Implants a smart choice.

To place an order or to learn more about the full product line of the Tatum Integrity Implant System, Call Tatum Surgical today!



Proudly Made In The U.S.A.

Integrity Tapered Implant



Integrity Implants

starting at:

\$150.00


Package includes Implant, Abutment, and Healing Cuff

1-888-360-5550

or visit us online

TatumSurgical.com

3D PRINTING:



A New Dimension of Implant Dentistry

By Brian Justice



Technology is driving change in every aspect of healthcare, particularly in implant dentistry. Few developments promise to have as much impact as 3D printing. Although current market penetration is only in the low single digits among dentists utilizing 3D printing in their practices, the revenue generated by medical 3D printing was \$660 million in 2016. According to *The Wall Street Journal*, that figure is projected to grow to \$1.21 billion by 2020.

What makes those figures even more intriguing is that dental implants represent 34% of those expenditures. While the adaptation of 3D printing in implant dentistry is still in its infancy, that's changing fast. Sales of 3D printers to the dental industry grew 75% from 2015 to 2016 alone.

Current usage and cost

Currently, 3D printing is being utilized primarily to create surgical guides, at a lower cost, and with a degree of accuracy equal to traditionally produced guides. What's more, advances in the design and manufacture of 3D printers have made it viable for a dentist to purchase a printer small enough to sit on a counter and produce guides in-house, bypassing external labs. This potentially saves money and time for both practice and patient.

It is not uncommon for surgical guides to cost between \$200 and \$800, depending on the complexity of the case and source. Guides produced

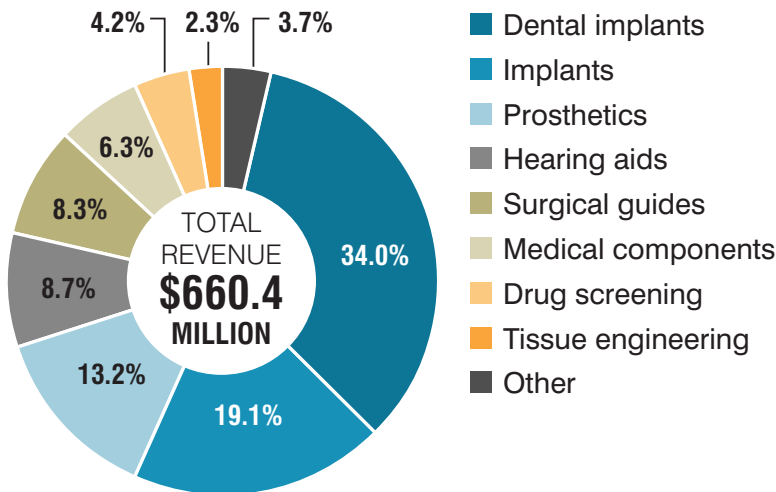
through 3D printing cost between two dollars and five dollars. Even when factoring in the costs of the scanning solutions and the software required, the overall expenditure remains relatively low and the benefits of printed surgical guides become obvious.

Some manufacturers require materials, usually a kind of resin, that are specifically formulated to their printers, just as the various brands of home copier/printer requires ink specific to that make and model. There are materials, however, that can be used across brands, further making in-office 3D printing increasingly practical.

As for the printers themselves, shoppers are largely dependent on sales reps and word-of-mouth, but there are independent sources of information relevant to the dental industry. Aniwaa is an online resource for researching and comparing 3D printing hardware by users' needs and budgets. "Think of us as IMDb of 3D printing," states their website. Their own researchers compile independent, relevant information and curate reviews to create a database of printers, scanners and filaments. They produce easily digestible "Best of" lists that can be sorted by search criteria, much like shopping on Amazon. But for the most part pricing is determined by how work-ready some models are — some require assembly — and capacity.

What It's Used For

Uses of 3-D printing in health care by share of revenue, 2016



* Figures are estimate/projection

Source: IndustryARC

Advances in the design and manufacture of 3D printers have made it viable for a dentist to purchase a printer small enough to sit on a counter and produce guides in-house, bypassing external labs.

Accuracy

Final implant positions, done freehand by even the most skillful and experienced clinicians, can deviate from the ideal position. Surgical guides make the placement of implants more precise, preventing undesirable results that can range from a less than ideal esthetic outcome to actual injury. The availability of 3D printed guides can increase the rate of reliable, consistent and satisfactory outcomes.

Formlabs, based in Boston, recently conducted an accuracy study of their own 3D printed surgical guides, which must be produced within very tight dimensional tolerances to be useful in clinical applications.

Formlabs printed a set of six surgical guides (four full arch guides and two quarter arch models) several times on several printers for a total of 84 surgical guides.

They were cleaned, post-cured, removed from supports and digitized. Once scanned, each guide was compared to its stereolithography (.stl) file, a

universal format for the surface scans of patients teeth. A difference map was produced using only the occlusal areas and surgical fixtures to ensure that only the relevant portions of the surgical guides were used in the calculations.

On average, approximately 93% of the occlusal surfaces and surgical features were within the desired ± 100 micron tolerance range. When the standard deviation of these measurements ($\pm 5\%$) was included, the two intervals of the distribution predicts that approximately 95% of surgical guides produced by the 3D printers utilized in the study meet the ± 100 micron tolerance range, suggesting that usable surgical guides can be produced in virtually every attempt.

Workflow Benefits

Additional benefits of 3D printed surgical guides include more control by the clinician. This allows hands-on customization of treatment protocols to each patient's needs and desired outcomes. Turnaround times are greatly reduced as well.

Contributing to this evolution is the increased accessibility of the printers themselves. They have been large, expensive and slow, requiring frequent upkeep and recalibration, and were still not entirely reliable.

"The biggest change in the field of dentistry is that these machines that used to cost hundreds of thousands of dollars can now be purchased for less than \$5000," said Dr. Brian Goodacre, Assistant Professor at Loma Linda University School of Dentistry, where he completed a residency in prosthodontics and implant dentistry. Although these new desktop models make 3D printing more accessible and useable, the inputs must still be designed and created by the dentist. Dr. Goodacre sees that as the driver of the decision to move production into the office or continuing to outsource it.

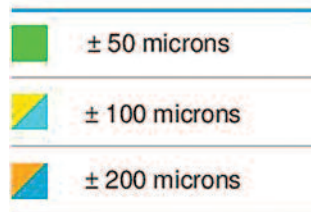
"If you are a dentist who sees 15 to 20 patients a day that can be a lot of work to make five to ten guides at a time. Depending on how busy the practitioner is, and if there is time after seeing patients during the day, they have to spend the next three or four hours designing guides and printing them. Some people just love 3D printing and they want to be involved with every step of it, and there will be others who are not interested in that and will send it to an outside lab to make it for them," said Dr. Goodacre.

The Future of 3D Printing and Implant Dentistry

For now, 3D printing is primarily utilized in the design of surgical guides. Research is underway, though, in achieving the "holy grail" of 3D printing for implant dentistry: actual 3D printing of crowns and bridges, as well as implants themselves directly from the printer and into the mouth. That scenario is years in the future, as viable materials are developed and the path to Food and Drug Administration (FDA) approval is navigated.

However, some interesting research is being done. For example, in 2015 the University of Groningen in

ACCURACY OF PRINT TO 3D MODEL



Source: Formlabs

the Netherlands developed a material with antimicrobial properties that make the possibility of 3D printed teeth more tangible. The test material was used in a 3D printer, then hardened with ultraviolet light. Upon exposure to saliva and streptococcus mutans it killed 99% of the bacteria present. The test was limited in terms of time and scope. Researchers also want to examine how the material reacts with toothpaste and determine if the 3D-printed plastic is strong enough to function as a tooth.

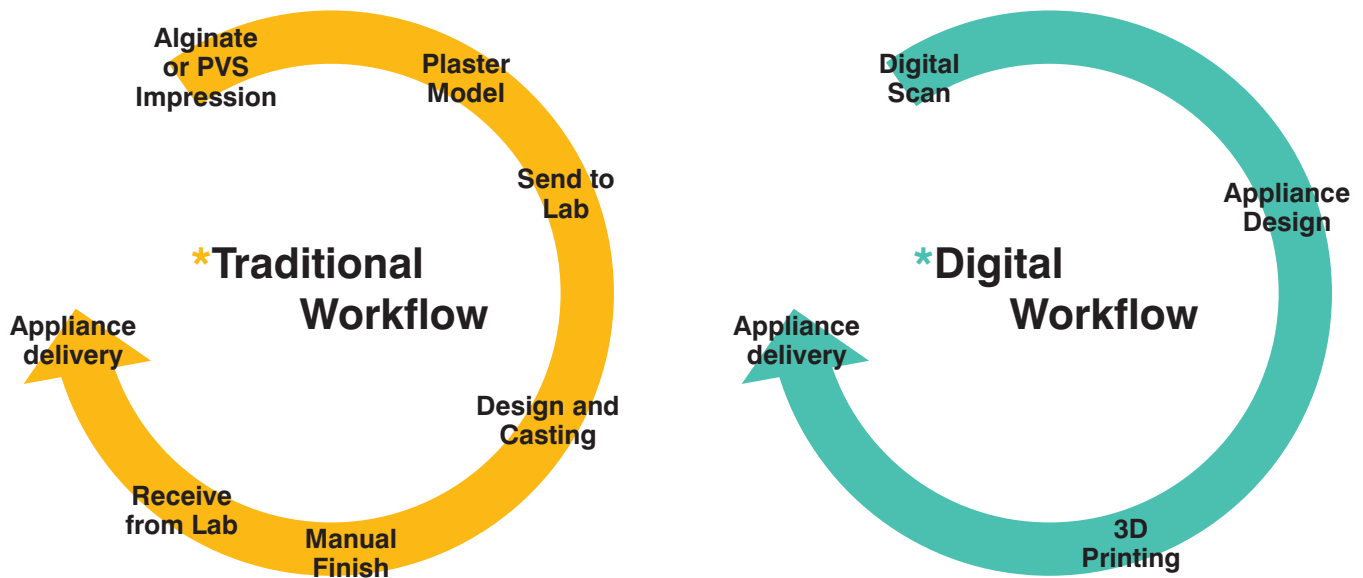
Work is being done in developing ceramics for 3D

printing. In just the last year, the Department of Ceramics and Refractory Materials at Aachen University in Germany conducted a study on 3D printing of zirconia powders. Though they concluded that zirconia powder wasn't a good solution for 3D printing dental appliances another technique, direct inkjet printing, was promising. "The novel technique (direct inkjet printing) has great potential to produce in a cost-efficient way, all-ceramic dental restorations at high accuracy and with a minimum of materials consumption," the research team stated.

Until then, 3D printed temporaries are being used but an actual crown, bridge or tooth that goes from a machine directly into a patient's mouth remains on the horizon.

"What it comes down to is the materials," said Dr. Goodacre. "There still remains development of a specific material that can be 3D printed but is strong enough, stable and retain color stability to permanently stay in someone's mouth, and get FDA approval. But give it time. It will be there." ●

Research is underway, though, in achieving the "holy grail" of 3D printing for implant dentistry: actual 3D printing of crowns and bridges, as well as implants themselves, directly from the printer and into the mouth.



How 3D printing can accelerate the workflow model.

Shopping Considerations from Aniwaa.com

Dental 3D printers can start at a few thousand dollars for resin desktop 3D printers (SLA or DLP), up to tens of thousands of dollars for metal 3D printers designed for direct production. Some manufacturers only make dental 3D printers while others have developed specific dental product lines.

Entry-level desktop SLA or DLP 3D printers start around \$1,000 and can be used to produce molds using a special casting resin. Industrial-grade dental additive manufacturing systems can cost up to tens of thousands of dollars. Dental 3D printers prices vary based on several factors:

Print quality: The higher the resolution offered by the 3D printer the better and often the more expensive the 3D printer.

Build volume: More expensive dental 3D printers usually offer a larger print volume, thus allowing

dental labs to optimize their production flow and increase their ROI by 3D printing a large number of dental appliances on the same build platform.

Dental 3D software: A special software is required to create custom dental implants based on a 3D scan of the patient's mouth. The dental 3D software is an important component of the digital dentistry value chain and can be expensive.

Reliability and repeatability: Perhaps the most important factor when it comes to using 3D printing for dental appliances production. Professional dental 3D printers must be able to consistently deliver high quality prints, especially in a dental lab environment where quality controls are frequent and a high production output is expected. Therefore, some dental 3D printers are more expensive than others because they offer this reliability.

Here are some options you might face in selecting a 3D printer:

Category:	Material	Minimum layer thickness
Do-It-Yourself/Kit	Pla	0 - 0.05 mm
Desktop	High Resistance	0.05 - 0.1 mm
Professional	Other Plastics	0.1 - 0.15 mm
Industrial	ABS	> 0.15 mm
	Liquid Resin	
	Sandstone	
Technology:		Features
Extrusion	Metal	Heated Print Bed
Material Jetting	Ceramic	Automatic Calibration
Binder Jetting	Paper	Closed Frame
	Edible	Dual Extruder
	Organic Living Cells	Full Color
Lamination:		
Resin	Textile	LCD Screen
Directed Energy Deposition		Touchscreen
Powder		On-Board Camera
3D Bioprinting		Mobile App
		3D Scanner
		CNC Mill



By Randy Alvarez

Lights, Camera, Action!

How to create educational videos to grow your implant practice.

Marketing for general dentists, oral surgeons, prosthodontists and periodontists has really changed since I wrote, directed and produced my first video 20 years ago. Today, I have directed and produced more than 4,000 videos for doctors that are featured on The Wellness Hour (wellnesshour.com). The videos have evolved, and my clients are now using their videos in innovative ways. Included in those

8 keys to video marketing

1. Place your videos on YouTube with a Google Adwords promotion.
2. Put patient testimonials on your website and on YouTube.
3. Show educational videos in your reception area.
4. Play targeted videos in patient rooms to view while they are waiting to be seen.
5. Air a long-form, half-hour video on local television (average cost \$200.00 per half hour ad spot).
6. Create Facebook ads with video testimonials.
7. Create an email campaign with educational video links, to send to all potential patients that aren't quite convinced to move forward with implant surgery.
8. Send education videos to all new patient consults to help lower their fears and gain rapport before they arrive at your office.

The most successful implant practices have video testimonials on their website and on YouTube.

changes is the explosion of distribution channels to deliver your videos to people that could benefit from dental implants. The direction medical and dental marketing seems to be going is in the use of educational and persuasive video to build the doctor's brand. The trend right now seems to be live streaming video and educational videos on the doctor's website, on YouTube, and part of a doctor's social media marketing.

I have studied advertising and marketing for more than 30 years. Advertising is not rocket science, but there is a science to moving humans to take action. I have paid close attention to those videos that produce the biggest ROI. Results are defined by how many new patients the video generates and how much revenue it brings into the practice. The videos that do the best are those videos that focus on results.



The most successful implant practices have video testimonials on their website and on YouTube.

Getting started

Announce to your team that you are going to start shooting patient testimonial videos using smart phones or a single-lens-reflex (SLR) camera on a tripod.

Begin with patients who are happy and vocal about their results. Your front office or your hygiene team knows who these patients are. Keep your videos under one minute and follow the guidelines below.

Use these patient testimonial videos on your site, in your reception area, on YouTube, on social media and to send them to all new patients.

Topics to discuss on videos in which the doctor provides education to patients include options for denture wearers, single-tooth implants, extractions and same day permanent teeth, as well as the dental implant process.

10 best tips for creating and directing a patient testimonial video

1. Ask the patient to smile and talk. They are sharing a positive story.
2. Begin the video with the patient describing how bad things were before their dental procedures. (No more than 10 seconds on how bad things were.)
3. Ask them to give you one to three life improvements because of their new improved smile. Examples: "I get

compliments on my smile every day." "I can eat salads now." (Rather than stating I eat foods I enjoy, make sure they are specific about the foods they can eat), or "I feel like I look younger." "I like what I see in the mirror." "Now I smile all the time!"

4. Ask them if they wish they would have done their work sooner.
5. Have the patient finish with comments about the customer service the practice provided (No more than 10 seconds).
6. Have the patient speak to the right or left side of the camera in an interview style.
7. Make sure that their teeth are well lit.
8. Frame the shot a bit off centered with room in front of their nose.
9. Eliminate your questions from the video.
10. Avoid open ended questions like "Tell us about your overall experience."

Randy Alvarez is the CEO of the Wellness Hour. If you would like more information or help with your videos, you can schedule to speak with Randy Alvarez and receive a free marketing evaluation, assessment and strategy session. Please contact Annamarie DeMaio at 760-434-5559 or email us at annamarie@wellnesshour.com. See more than 4,000 interviews with doctors on www.wellnesshour.com.



By Frank Recker, DDS, JD

The Changing Legal Horizon

Editor's Note: *The following is a summary of the report given by Dr. Frank Recker at AAID's 2017 Annual Business Meeting held in San Diego, California in conjunction with the Academy's 66th Annual Education Conference. We thank Dr. Recker for providing updates on his activities that are included in this summary.*

As reported to the Board of Trustees at the annual meeting in San Diego, the legal environment related to specialty advertising is in a state of flux, largely due to the June 2017 decision of the 5th Circuit Court of Appeals. That court upheld the decision of the district court in Austin finding that the Texas regulation being challenged was unconstitutional by prohibiting specialties other

change that would recognize the American Board of Dental Specialties (ABDS) as a specialty certifying entity. Although declining to adopt the petition, the Board also stated that it was imposing an indefinite moratorium on enforcing the regulation at issue. Therefore, at present, Diplomates of the ABOI/ID can advertise as specialists in New Jersey as could other Diplomates of ABDS recognized boards.

The North Carolina Board reported that it intended to comply with the decision of the 5th Circuit, recognizing that they had to follow their regulatory process for amending the regulation limiting specialty advertising to ADA specialties.

The Executive Director of the Oklahoma Board, Susan Rogers, reported that her Board is seriously considering adopting the ABDS for purposes of specialty advertising. As an attorney and former prosecutor, Ms. Rogers is well informed relative to the recent court decisions and the First Amendment issues at hand. She has extended an invitation for AAID legal counsel to appear at the January Board meeting to discuss the issues.

Jill Stuecker, MPA, Executive Director of the Iowa Board of Dentistry, also advised that the Board is giving serious consideration to adopting the ABDS, in addition to the ADA recognized

The legal issues over specialty advertising are unquestionably, and justifiably, causing boards to take a serious look at their specialty advertising restrictions and potential legal vulnerability.

than American Dental Association (ADA) recognized specialties from advertising as such. Developments in other states were also reported by Dr. Recker, legal counsel for the AAID.

The New Jersey Board declined to accept a formal petition seeking a rule

specialties. She has invited AAID legal counsel and Craig Busey, General Counsel of the ADA, to give a joint presentation to the Board on January 26, 2018.

Mr. Busey and Dr. Recker gave a joint, main podium, presentation at the American Association of Dental Boards annual meeting in Atlanta. The topic was specialty recognition and the current status of the ADA and ABDS as specialty certifying entities. Busey encouraged the attendees to recognize an independent entity such as the ABDS, in addition to the ADA recognized specialties. He explained the history of ADA Resolution 65 and the motivations for its adoption.

In late October, Dr. Recker and other participants, including Dr. Michael Mashni, a dental anesthesiologist and a newly elected president of the ABDS, gave a presentation at the American Dental Education Association meeting in Columbus, Ohio. The audience of educators listened attentively and also heard Dr. Anthony Ziebert, Senior Vice President of the ADA responsible for oversight of the ADA's Council on Dental Education and Licensure and Commission on Dental Accreditation, speak on the topic of specialty recognizing entities in multiple professions, the majority of which are independent and not affiliated with any related trade association such as the ADA. He also recognized the ABDS as an independent specialty recognizing entity that should be accepted by the profession of dentistry. He noted that sole reliance on the ADA specialty process was ill advised.

AAID's pending litigation against the Indiana Board of Dentistry is progressing into depositions of the Board members and related discovery. The Indiana Board has

not attempted to resolve the litigation over their "ADA only" specialty regulation but has engaged in numerous stall and delay tactics calculated to impede the proceedings. Dr. Craig Cooper is the plaintiff in this litigation, along with the AAID.

The Ohio Board had ostensibly expressed interest in the ABDS, and AAID counsel has worked with the Board to educate and inform the Board members of the evolution of the law relating to commercial free speech and the formation and operation of the ABDS. Dr. Jaime Lozada, then president of the ABDS, gave an "in-person" presentation about the ABDS as a specialty recognizing entity this past summer. These educational efforts have spanned a year or more. Despite showing serious interest in avoiding litigation, the Board surprisingly opted to conduct a survey in the hope of compiling empirical evidence of harm to consumers if they amended their "ADA only" specialty regulation. The litigation against the Ohio Board is pending as of this printing.

The Massachusetts Board of Dentistry adopted a rule that accepts specialties recognized by the ABDS in addition to ADA. The formal enactment of that amended regulation is pending completion of the administrative approval process.

The legal issues over specialty advertising are unquestionably and justifiably causing boards to take a serious look at their specialty advertising restrictions and potential legal vulnerability. The AAID has directed legal counsel to target those states that show little concern or interest in accepting Diplomates of the ABOI/ID as specialists in implant dentistry, along with the other members of the ABDS. ●



By James Gibney,
DMD, FAAID, DABOI/ID

24-Hour Teeth

Editor's Note: *Dr. James Gibney won the Table Clinic Competition at the American Academy of Implant Dentistry's 66th Annual Education Conference held in San Diego, California, in October 2017.*

INTRODUCTION

Immediate load of dental implants for the fully edentulous patient is gaining popularity within the profession and has proven to be a predictable treatment modality.^{1,2,3} Originally designed to treat the fully edentulous mandible in a cost-effective manner, the concept has been expanded to include treatment of both fully and partially edentulous patients sometimes necessitating removal of significant amounts of alveolar bone.⁴ Once this bone has been removed the resulting prosthesis often requires replacement of both hard and soft tissue, necessitating the use of pink porcelain or acrylic to recreate the lost gingiva. By using osteotomes and a guided bone expansion technique many of the challenges associated with restoring the missing soft tissues can be avoided.

ABSTRACT

The use of osteotomes to expand bone is not a new concept, dating back over 40 years. Roberts, Tatum, Summers and Hahn have all contributed to our collective understanding of the use of osteotomes in implant site development.^{5,6,7,8} The classic bone expansion technique is performed using very small soft tissue incisions or flapless procedures to avoid reflecting the periosteum. By maintaining the periosteum, the blood supply to the alveolar bone is preserved and the bone is supported as it expands.⁹

Two modifications to the osteotome bone expansion technique aim to simplify the procedure and improve surgical outcomes.

1. The first modification is the addition of a surgical guide. CT-derived surgical guides have proven to enhance the ability to place implants in the proper position in areas of adequate bone.¹⁰ In areas of inadequate bone, for the classic bone expansion technique to be successful, the initial bone incision must split the buccal and palatal cortical plates. With limited visibility of the flapless procedure, the ability to precisely split the cortical plates in an atrophic ridge is highly dependent on the skill of the surgeon. The addition of a prosthetically driven surgical guide aims to improve the predictability of the initial bone incision and forces the dentist to decide on the implant locations relative to the final restorations prior to surgery.¹¹ It also aims to reduce positional failure caused by poor treatment planning or surgical execution.¹²
2. The second modification to the technique is the immediate loading of the implants. A review of the literature suggests that insertion torque values of 35 Ncm or greater will support an immediate load protocol.^{13,14,15} This initial stability must be maintained throughout the integration period. For predictable osseointegration to

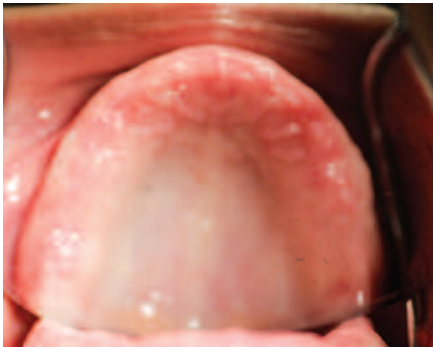

Figure 1 Edentulous maxilla

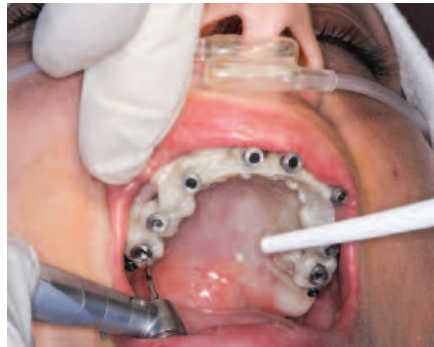

Figure 2 Surgical Guide

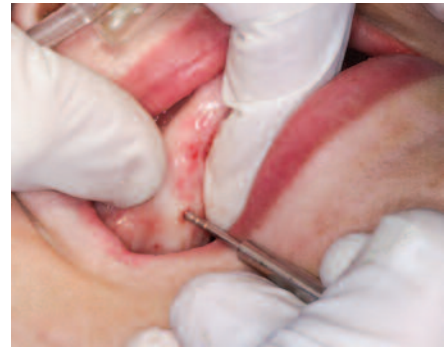

Figure 3 Initial osteotomy

occur, motion at the bone-implant interface must be kept below 150 microns.^{15,16,17} In patients with a fully edentulous arch opposing natural teeth immobilization of the implants has proven to be very challenging in light of the fragility of the expanded bone and the lack of occlusal stops to protect the implants from the opposing dentition. The modification of the technique to include immediate load aims to protect the implants during the integration period. Several other factors are considered to reduce the risk of implant movement, including dietary restrictions, cross arch stabilization and elimination of parafunctional habits.

MATERIALS AND METHODS

SURGICAL GUIDE

Fabrication of the surgical guide combines clinical assessment, diagnostic casts, three-dimensional imaging and digital prosthesis design. The technique involves making a study model of the proposed arch to be treated. A vacuum formed baseplate is fabricated over the study model. Surgical guide sleeves are attached to the baseplate with sticky wax and the complex is scanned with a desktop scanner to generate an .stl file. The .stl file is imported into design software and a PMMA restoration is designed. After the PMMA restoration is milled it is seated on the guide sleeves and attached with cold cure acrylic. This is seated in the mouth and a cone beam CT is taken. The radio-opaque guide sleeves indicate the proposed position of the abutments and the lumens show the orientation of the initial bone incisions. Implants are planned relative to the abutment positions and orientation of the bone incisions.

IMMEDIATE LOAD

Using the surgical guide and a flapless technique, initial bone incisions are made with a pilot drill through each of the openings of the surgical guide. These pilot holes are expanded using a series of osteotomes of increasing diam-

eter. Once the desired dimension of the osteotomies has been reached, implants are placed and insertion torque is recorded. Abutments are placed and impressions made. Stone models are poured and scanned using a desktop (box) scanner generating .stl files of the working model, the opposing model and the mounted models. A full arch one-piece provisional restoration is designed and milled out of PMMA. After clinical adjustments are finished, the PMMA restoration is cemented with permanent cement. The patient is placed on dietary restrictions for 16 weeks, beginning with a liquid diet for 4 weeks followed by a soft diet for 8 weeks and semi-solid foods for 4 weeks. All dietary restrictions are lifted after 16 weeks. After the integration period, full contour zirconia restorations are fabricated.

RESULTS

Eight consecutive maxillary arches were reviewed: 5 fully and 3 partially edentulous; 53 Tatum Surgical “T” implants were placed and immediately restored with PMMA provisional restorations. All 53 implants are loaded and still in function. (100%) Three patients required sinus grafts and each had two additional implants placed that were not immediately loaded. Including the six implants not immediately loaded all 59 maxillary implants are still in function.

Twelve mandibular arches were treated with a similar immediate load protocol using conventional osteotomy preparation with flap reflection. 87 implants were placed into 12 mandibular arches; six fully edentulous and six partially edentulous. Six of the 12 patients lost at least one implant; one patient suffered a catastrophic failure and lost all eight implants.

In total, of the 140 immediate load implants placed 126 are still in function (90.0%). When evaluated by type of implant 122 of 127 “T” implants are still in function (96.0%) and four of the 13 “One Piece” implants are still in function (31% success). Of the 14 implants that were lost eight were in one patient.

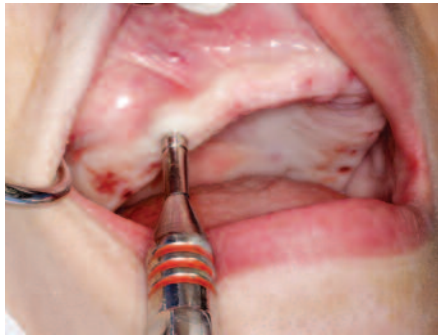


Figure 4 Final Osteotome

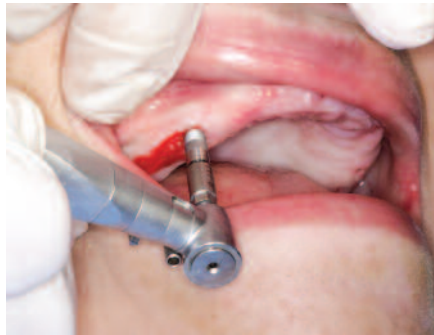

Figure 5 Implant Placement

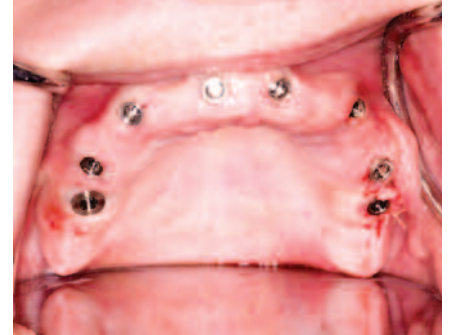

Figure 6 Immediate Post-op

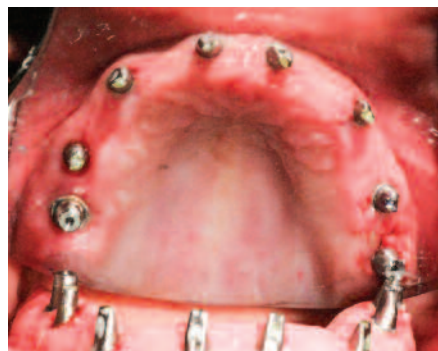

Figure 7 Abutments placed

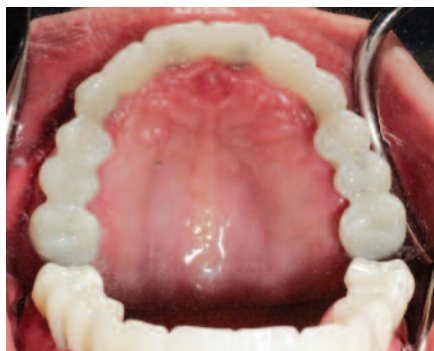

Figure 8 Immediate load provisional

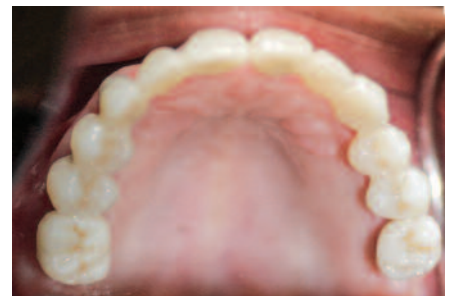

Figure 9 Final Restorations

CONCLUSION

The underlying objective of the technique is to restore the patient to normal contour, comfort, health, function and esthetics. With this goal in mind, steps are taken to avoid altering the anatomy in such a way that would compromise the final prosthetic result. The preliminary findings of this study indicate that an immediate load protocol using guided bone expansion in the maxilla may produce clinically acceptable results. Preliminary data suggests that the “T” implant is a better choice for immediate load than the “one piece” implant. ●

REFERENCES

1. “All-on-Four” Immediate-Function Concept with Brånemark System® Implants for Completely Edentulous Mandibles: A Retrospective Clinical Study Paulo Maló, DDS; Bo Rangert, PhD, MechEng; Miguel Nobre, RDH). *Clinical Implant Dentistry and Related Research*, Volume 5, Supplement 1, 2003; 2-8
2. Schnitman PA, Wöhrle PS, Rubenstein JE, DaSilva JD, Wang NH. Ten-year results for Brånemark implants immediately loaded with fixed prostheses at implant placement. *Int J Oral Maxillofac Implants* 1997; 12:495-503.
3. Balshi TJ, Wolfinger GJ. Immediate loading of Brånemark implants in edentulous mandibles. A preliminary report. *Implant Dent* 1997; 6:83-88.
4. All-on-4 Immediate-Function Concept with Brånemark System® Implants for Completely Edentulous Maxillae: A 1-Year Retrospective Clinical Study Paulo Maló, DDS; Bo Rangert, PhD, MechEng; Miguel Nobre, RDH *Clinical Implant Dentistry and Related Research*, Volume 7, Supplement 1, 2005; 88-94
5. Roberts, R.A. *Pacific Implant Surgical Manual* 1990
6. Tatum H. Maxillary and sinus implant reconstructions. *Dent Clin North Am.* 1986;30:209-229.
7. Summers RB. The osteotome technique: part 2—The ridge expansion osteotomy (REO) procedure. *Compendium.* 1994;15:422-426
8. Hahn J. Clinical uses of osteotomes. *J Oral Implantol.* 1999;25:23-29.
9. Chanavez M. Anatomy and histophysiology of the periosteum: quantification of the periosteal blood supply to the adjacent bone with 85Sr and gamma spectrometry. *J Oral Implantol.* 1995;21:214-219.
10. Ganz, S.D., CT Derived fabrication of surgical guides. *Journal of Oral and Maxillofacial Surgery* 63:59-71 2005
11. Small, B.W. Surgical templates for function and esthetics in dental implants. *Gen Dent.* 2001 Jan-Feb;49(1):30-2, 34
12. Chee, W, Jivraj, S *Failures in Implant Dentistry British Dental Journal* 202, 123-129 (2007)
13. de Olivera *et al* Dental Implants with immediate loading using insertion torque of 30 Ncm: A systematic review *Implant Dentistry* Volume 25, Number 5 2016

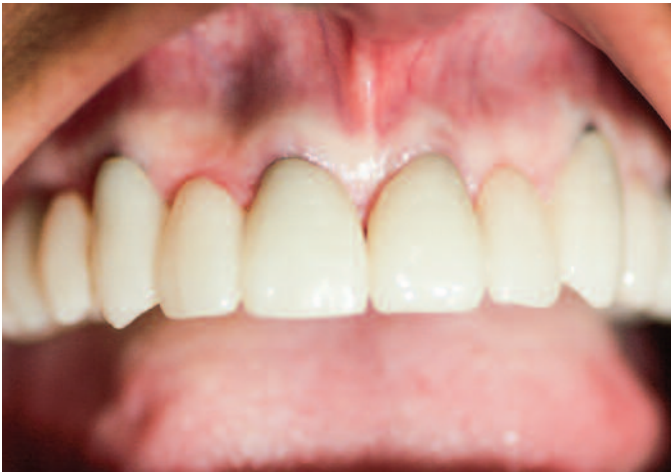

Figure 10 Final restorations

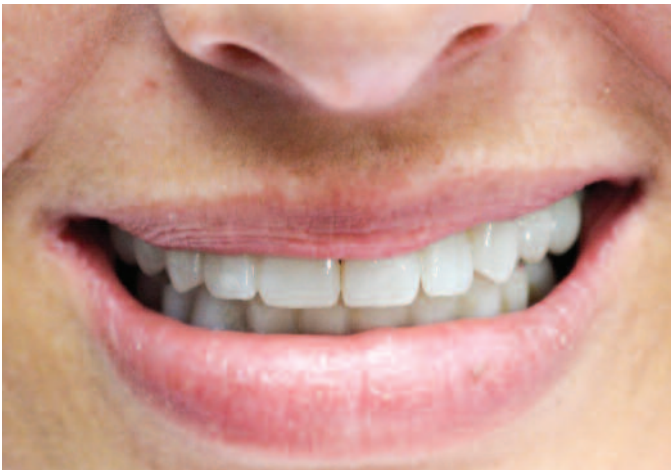

Figure 11 Smile

14. Rizkallah, N., Fischer S., Kraut, R.A., Implants in the maxilla: A retrospective study *Implant Dentistry*, Volume 22 Number 3 250-254 June 2013
15. Siebers, D. Gehrke, P. Schliephake, H. Immediate function in Dental Implants *Journal of Dental Implantology Original Study* – ZZI 03/2011
16. Cochran DL. The evidence for immediate loading of implants. *J. Evid Base Dent Pract* 2006;6:155
17. Chowdhary R, Chowhary N, Change in Paradigm: Dental Implant Loading International *Journal of Oral Implantology and Clinical Research*, Sept-Dec 2010;1(3):141-145



Teeth Tomorrow
The Permanent Solution®

**THE FASTEST
GROWING NETWORK
OF ADVANCED
IMPLANT DENTISTRY**



**EXPAND YOUR PRACTICE
WITH TEETH TOMORROW®**

**OVER 50 MILLION AMERICANS WILL
BE CANDIDATES FOR THE
TEETH TOMORROW® PROCEDURE BY 2020.**

Don't miss this exceptional opportunity to grow your existing practice by providing our life-changing treatment.

TeethTomorrow.com/Join

**BENEFITS OF JOINING THE
TEETH TOMORROW® NETWORK**


- Provides your practice with an **additional revenue opportunity** by creating a stand-alone business that attracts patients seeking full-arch restorations
- Conducts **comprehensive training** for Doctors and Staff to stay current on the best, proven surgical and clinical protocols
- Provides **member discounts** on Prettau® Zirconia Bridges from Tischler Dental Lab
- Directs prospective patients to your practice through a National Call center
- Protects your investment by limiting franchises to 250 exclusive territories

**GEOGRAPHICALLY PROTECTED TERRITORIES
ARE FILLING UP FAST**

Visit TeethTomorrow.com/Join to see available territories.
Contact the Teeth Tomorrow® Network Support team at **845-679-1280** to find out more.



Visit TischlerDentalLab.com
to find out more about the World Leader in Prettau® Zirconia Full-Arch Bridges



American Academy of Implant Dentistry selects ePoster and Table Clinic Winners

The American Academy of Implant Dentistry announces the winners of the ePoster and Table Clinic competitions held at the recently concluded 66th AAID Annual Conference. The winners were selected by a panel of experienced implant dentists from among 27 ePoster entries and 17 table clinic presentations. The 67th Annual Conference, which will be held September 26 – 29, 2018, in Dallas, Texas, will again include ePosters and table clinics. Online access to submit entries will be available in May 2018, at aaid.com.

Table Clinic Winners

1ST PLACE:

James W. Gibney, DMD
“24 Hour Teeth”

2ND PLACE:

Jeni Heselbarth, DDS; Michael Pruett, DMD; Andrew J. Hamilton, DMD; John F. Coleman, DMD
“Do Material Things Matter? A Review of Metal and Zirconia Implant Abutments”

3RD PLACE:

Andrew G. Lum, BS; Yumi Ogata, DMD, DDS, MS; Sarah E. Pagni, PhD, MPH; Yong Hur, DMD, DDS, MS
“Observations in Lateral Wall Thickness Among Schneiderian Membrane Perforations: A Cone-Beam Computer Tomographic Evaluation”

ePoster Winners

1ST PLACE:

Zeeshan Sheikh, BDS, Dip. Dh, MSc, PhD; Gang Chen, PhD; Dr. Robert Young, BSc, DIC, PhD; Marc Grynepas, MSc, PHD; Michael Glogauer, DDS, Dip.Perio, PhD

“Improved and More Predictable Vertical Bone Augmentation Using Synthetic Dicalcium Phosphate Block Grafts Containing a Novel Bisphosphonate — EP4a Conjugate Drug (C3).”

2ND PLACE:

Andrew Flipse, DMD; Cody Gronsten, DDS; Chris Kondorossy, DDS; Anthony Olsen, DDS; Jose Pedrosa, DMD; Steven Puffer, DMD; Hilt Tatum Jr., DDS
“Treatment of the Atrophic Maxilla: A Case Study Utilizing the NIRISAB Approach”

3RD PLACE:

Yasser S. Alzahrani, BDS; Brian J. Goodacre DDS; Jaime Lozada, DDS; Joseph Y.K. Kan, DDS, MS
“Surgical Guide for Harvesting Bone Block Graft”

An Entirely New Digital Approach to a Definitive Full-Arch

HYBRIDGE[®] XD

EXPRESS DIGITAL

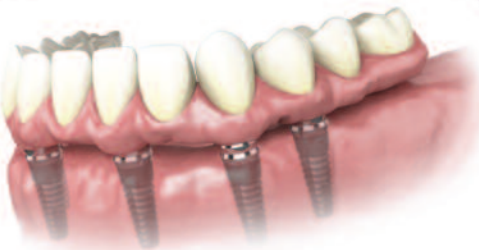"The Hybridge XD protocol allows me to complete a full arch case in just two weeks with only four clinical hours. That includes just one appointment post surgery to deliver the final prosthesis. Hybridge provides the support I need to ensure my cases are predictable and I exceed my patient's expectations."

Dr. Adam Kimowitz, *Certified Hybridge Provider*

Finally, a digital full-arch protocol that is simple and predictable.

4 HOURS

Total doctor time
per case



1 APPT

Post surgery to
final prosthesis

To learn more: call **585-319-5400** or visit **HybridgeNetwork.com/XD**



Editor’s Note: Because of busy schedules, you may not have time to read the dozen or so articles in each issue of the *Journal of Oral Implantology*. In this section of *AAID News*, we selected a few articles that have broad applicability to the daily practice and provide a brief summary of key points so you can decide if you wish to read the complete article. The following articles are from Volume 43, Issue 5 (October 2017).

RESEARCH

Evaluation of Fracture Resistance of Varying Thicknesses of Zirconia around Implant Abutment Cylinders

The use of zirconia has been growing in single- and multiple-unit implant-supported restorations. Chipping of layered porcelain has been the most commonly reported clinical complications with zirconia-based restorations. This research, funded in part through a grant from the American Academy of Implant Dentistry Foundation, was designed to evaluate the resistance to fracture of zirconia with different wall thicknesses luted to implant components. The conclusion of the study was that given average occluding forces in humans, a minimum thickness of 0.5 mm to 1 mm of the particular type of zirconia used in the study may be sufficient to resist fracture of the zirconia prosthesis around this area of stress and minimum volume of material.




FIGURE 4. Fractured specimen under load.

Cheryl J. Park, Jin-Ho Phark, Winsont W. Chee, Evaluation of Fracture Resistance of Varying Thicknesses of Zirconia around Implant Abutment Cylinders, *Journal of Oral Implantology*. 2017;43(5):338-332.

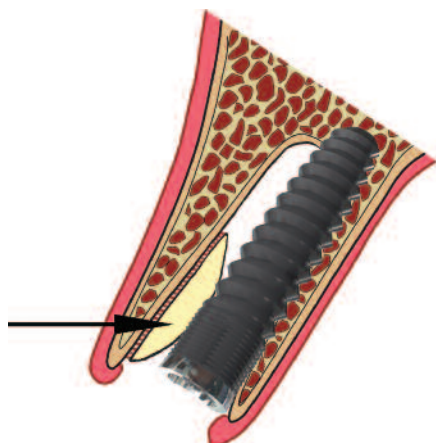

FIGURE 1. Diagrammatic representation of the socket-shield technique: The black arrow indicates the root fragment retained to serve as a “socket-shield” to prevent resorption of buccal bone. Placement of implant is palatal/lingual to this root fragment.

LITERATURE REVIEW

Current Evidence on the Socket-Shield Technique: A Systematic Review

The socket-shield technique has been claimed to help preserve the buccal bone after extraction. The method involves intentionally retaining a buccal root fragment at the time of extraction, which would act as a shield that preserved the buccal bone from resorption. An immediate implant was then placed palatal to the root fragment. The authors conducted a systematic review of the literature to determine the biological plausibility and long-term clinical prognosis of the socket-shield technique.

The authors concluded that overall evidence in support of the socket-shield technique seems limited at present. Histologic evidence indicates rapid bone loss, failure of osseointegration, formation of cementum, and periodontal ligament or periodontal ligament-like fibrous tissue on implant surfaces in proximity to the shield, weakening the biological plausibility of this technique.

Amit S. Gharpure, Neel B. Bhatavadekar, Current Evidence on the Socket-Shield Technique: A Systematic Review, *Journal of Oral Implantology*. 2017;43(5):395-403.

CASE LETTER

One-Tooth One-Time (1T1T): A Straightforward Approach to Replace Missing Teeth in the Posterior Region

This Case Letter describes two patients, consecutively treated, using the same protocols. The treatment involved Polymer-infiltrated ceramic network (PICN) CAD-CAM composites along with intraoral scanning of single-unit implants right after surgery and chairside manufacturing of a PICN crown allowed the delivery of a resilient final tooth on the same day.

France Lambert, Amélie Mainjot, One-Tooth One-Time (1T1T): A Straightforward Approach to Replace Missing Teeth in the Posterior Region, *Journal of Oral Implantology*. 2017;43(5):371-377.

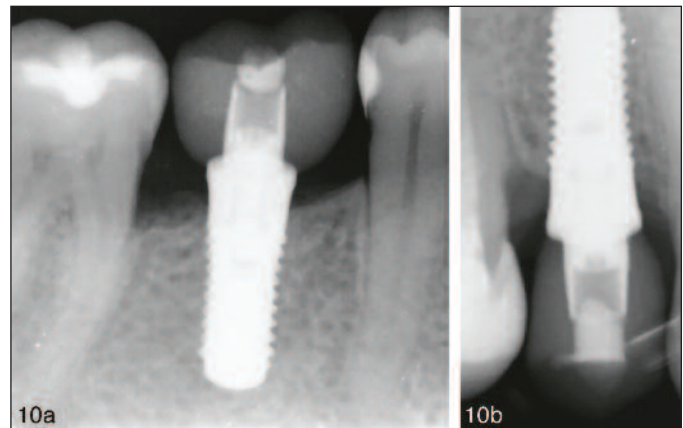


FIGURE 10. Radiologic outcomes at 1 year and 6 months, respectively. Note very stable peri-implant bone levels. (a) Case 1. (b) Case 2.

CLINICAL

Effects of Four Different Crown Materials on the Peri-Implant Clinical Parameters and Composition of Peri-Implant Crevicular Fluid

Although it is well known that different crown materials vary in appearance, metal-porcelain binding force, or hardness, there have been no related reports on whether the long-term implant health is related to the crown material. This study compared four types of crown materials by investigating peri-implant clinical parameters and the composition of the peri-implant crevicular fluid to predict the best crown material option for long-term healthy implants. According to the results of the study, zirconia all-ceramic titanium porcelain-fused-to-metal showed greater biocompatibility than cobalt-chromium porcelain-fused-to-metal and aurum platinum porcelain-fused-to-metal.

Shu-Juan Yu, Wen-Ling Shan, Yu-Zhao Liu, Ziao-Yan-Huang, Guo-Zhong Shu, Effects of Four Different Crown Materials on the Peri-Implant Clinical Parameters and Composition of Peri-Implant Crevicular Fluid, *Journal of Oral Implantology*. 2017;43(5):337-344.

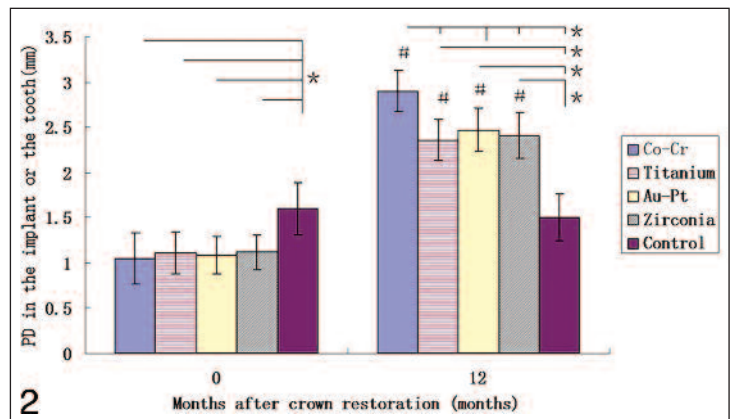


FIGURE 2. Comparison of probing depth among the different crown material groups before and after crown restoration. # $P < .05$ for the comparison with other groups during the same period. # $P < .05$ between before and after crown restoration in the same group.



EXCELLENCE IN IMPLANT EDUCATION FOR THE 67TH YEAR

AMERICAN ACADEMY OF IMPLANT DENTISTRY

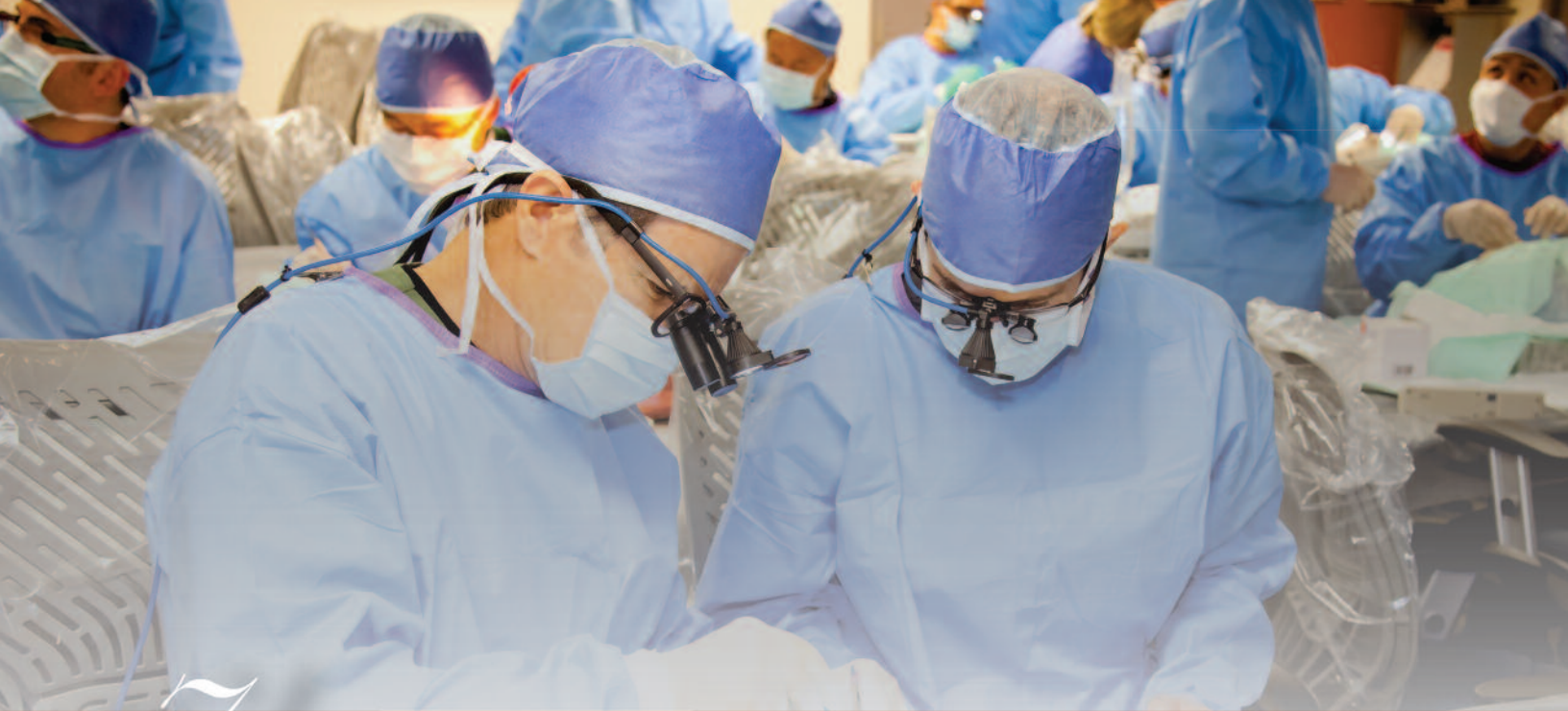Practical Education for the Practicing Implant Dentist[®]

IMPLANT DENTISTRY

T H E F U T U R E I S N O W

SEPTEMBER 26-29, 2018 | HYATT REGENCY DALLAS | DALLAS, TEXAS

www.aid.com/aid2018 | [#aid2018](https://twitter.com/aid2018)



17th ANNUAL COMPREHENSIVE PROGRAM IN IMPLANT DENTISTRY

SESSION I: April 2018 • SESSION II: May 2018 • SESSION III: June 2018

Key Educational Objectives

Surgery-related topics

Surgical anatomy; bone physiology; patient evaluation for implant treatment; risk factors; vertical and horizontal spaces of occlusion; bone density; implant surgical placement protocols; computer-guided placement and restoration; immediate loading techniques; mini implants; bone grafting before, during, and after placement; alveolar ridge expansion with split cortical technique; guided bone regeneration; sinus lift through the osteotomy site, and the lateral window; block grafting; chin block graft; BMP-2/ACS grafts with titanium mesh.

Prosthodontics-related topics

Impression techniques, restorative steps for implant fixed partial dentures, implant prosthodontics for fully edentulous patients, high-water design, bar overdenture, biomechanical principles, biomaterials, CAD/CAM designs, implant occlusion and more.

Hands-on & Live Surgeries

Hands-on pig jaw suturing & bone grafting workshops using regenerative materials are performed by the class and in live surgery demos by faculty.

Program Includes

Three 6-day sessions, 300 CE units, program certificate issued by the University of Nevada - Las Vegas (UNLV), hands-on workshops, live surgical demos, online education module with 25+ surgical videos, 50+ PowerPoint presentations, literature review, and special product discounts.

Expert Faculty

Dr. Louie Al-Faraje, DABOI, Program Chair
Dr. James Rutkowski, PhD, DABOI
Dr. Mamaly Reshad, Prosthodontist
Dr. Christopher Church, MD
Dr. Philip Kroll, MS
Domenico Cascione, CDT

Visit website for bios and more faculty.



Easy online registration at www.ImplantEducation.net or by phone at (858) 496-0574



Approved PACE Program Provider FAGD/MAGD Credit
Approval does not imply acceptance by a state or provincial
board of dentistry or AGD endorsement
8/1/2017 to 7/31/2020. Provider ID# 108066



ADA CERP is a service of the American Dental Association to assist dental
professionals in identifying quality providers of continuing dental education.
ADA CERP does not approve or endorse individual courses or instructors, nor
does it imply acceptance of credit hours by boards of dentistry.



This activity has been planned and implemented in accordance with the
standards of the Academy of General Dentistry Program Approval for
Continuing Education (PACE) through the joint program provider approval of the
UNLV School of Dental Medicine and California Implant Institute. UNLV School of
Dental Medicine is approved for awarding FAGD/MAGD credit.* Provider 213111



PRESIDENT'S MESSAGE



David G. Hochberg,
DDS, FAAID, DABOI/ID
President, American Academy of
Implant Dentistry

"It's All About the Patient"

Editor's Note: *Inaugural Address presented October 17, 2017, at 66th Annual Business Meeting of the American Academy of Implant Dentistry*

Thank you, **Dr. Shankar Iyer** for your year as AAID President. As you noted in your Annual Report, we accomplished a good deal this year. You've set things in motion that will keep us accomplishing a lot for years to come. It was your leadership as well as your many, many, many emails from lands far away that helped to guide this Academy through a year of change. Remember, you were the first President to work with three Executive Directors!

present on the dais, family and friends. To our newly credentialed members, I join others in offering congratulations!

Before I begin, I would like to recognize my wife, Eleanor, who has provided me with her friendship, her guidance and our son, Martin. Most importantly, she has given me her love and support throughout my career and 40 years of marriage...and, most notably, as you can see, she picks out great ties!

In 1970, when a patient arrived at a dentist's office with a missing tooth, the area was restored with a fixed bridge with the adjacent, healthy teeth filed down. Statistics show that within seven to ten years, the restoration exhibited recurrent decay, and, in many cases, the loss of one of the abutment teeth. The result was another bridge was fabricated and the size, span and involvement of the support teeth would increase. Many dentists found their patients suffering from a domino effect, with additional tooth loss often leading to an edentulous state.

Today, this is no longer the case! A single implant from day one avoids this horrible scenario!

That is because of the pioneers of this Academy and our dedicated membership. We are the American Academy of Implant Dentistry and have educated the entire profession, helping millions of patients throughout the world.

You'll smile, knowing this Academy appreciates your affiliation and wants your education and expertise to translate into patients, who benefit from your skills.

On behalf of the AAID Board, membership and me, we thank you for your time, your expertise, your commitment, and for passing the gavel to me with the AAID on the right track!

It's a pleasure to stand before the membership, the Board of Trustees, the Executive Committee, the AAID staff, all

Today, dental implants have become the standard of care. Our organization is the driving force. Yes, it's the AAID we have to thank!

The reason that so many patients have benefited and thank us is because our members, along with the guiding principles of this Academy, have been and remain, about the patient!

When **Drs. Aaron Gershkoff** and **Norman Goldberg** placed their first subperiosteal implant some 68 years ago, it was about the patient.

When, **Dr. Leonard Linkow** brought dental implants front and center on the world stage, it was about the patient.

When, **Dr. Hilt Tatum** developed a technique for lifting the maxillary sinus and augmenting it with bone (how incredible was that), it was about the patient.

And when **Dr. Carl Misch** took all these advancements, added some of his own, and standardized them by creating specific protocols that provided predictable outcomes for us all, it too was about the patient!

Not only were all these individuals outstanding leaders in the field of dental implants, they were all presidents of this Academy. While I'm honored to join their ranks and although my scientific contributions are none to be mentioned, I too, believe the patient is the focus of all our efforts. To be able to stand with these past leaders is thrilling.

But, if it's all about the patient, does the patient know who we are? Do they know what we have to offer? Have we kept all of this a secret from the public? Do they purposely seek out an AAID or ABOI credentialed member to provide their implant care?

The Academy's leadership believes we can do better and is letting the secret out. Breaking News: The AAID has been around for 67 years!!

Your Academy is undertaking a marketing campaign designed to remedy this situation. We want to add value to our membership and to your hard earned credentials. Wouldn't it be music to the ears of all members to hear your front desk say that new patients are on your book, "because they want to see an AAID credentialed member."

You'll smile, knowing this Academy appreciates your affiliation and wants your education and expertise to translate into patients, who benefit from your skills.

Our goal, is to engage the public, let them know that there is a difference between the dentist who offers dental

implants at a "discount special" after taking a weekend course and a dentist who is credentialed by the AAID!

The public is inundated with choices on a daily basis, on CNN, from mailers and from billboard signs. While this doesn't happen overnight, we need to answer the lay person's question: "Why choose us?"

In doing so, there's a two-fold payoff.

The first and remember, because it's all about the patient, he/she will be able to make an educated decision as to their dentist's qualifications in the field of implants. In turn, the AAID benefits. When the public demands credentialed dentists, young dentists interested in implant placement and restoration will want our credentials in order to meet this public demand. It's about more patients in the chair receiving the benefits of our skills!

We are committed to getting this done!

So, how and why do I stand before you today? I want to share a story with you and it may sound similar to yours. I had a mentor. We talk about mentorship all the time. Mine, was a periodontist, Dr. Edward Sugarman. I had just graduated from Emory University School of Dentistry and started my very first position as a general dentist in the Sugarman's group periodontal-focused practice. Many in the room may recognize Edward's last name. His father was Dr. Marvin Sugarman, a pioneer in periodontology, going back to the 1940s. In 1980, at that time in my career, I didn't know what an implant was. But, I found out quickly, Dr. Edward was one of the very first periodontists, who recognized that patients could benefit from dental implants and he offered those services. My interest peeked one day when I heard something in the office. I was in the operatory next to his, when I heard a loud tap, tap.

I thought someone was hammering a nail into the wall. When I got up to see what was going on, I saw Edward with a mallet seating a blade implant — an image I will never forget and the reason why I'm here today. He, told me about the AAID. He said, "David, you're a general dentist. You need to join the AAID and make sure you earn their credential." That was it, I never looked back. We both went to Florida to attend a subperiosteal forum, featuring **Drs. Leonard Linkow, Bob James, and Carl Misch**. I returned to Atlanta and placed my very first implant: a subperiosteal in an atrophic mandible.

I continued taking courses with **Drs. Duke Heller** and **Jack Hahn** and learned about root form implant placement early in 1984.

However, my personal “big leap” occurred when one of our past presidents, **Dr. Terry Reynolds**, started the very first MaxiCourse®. It was in Augusta, Georgia, at the then Medical College of Georgia, a drive down the road from my hometown of Atlanta. In fact, past president **Fran Ducoin**, along with **Dr. Raul Mena** attended with me. This course taught me the necessary skills and enabled me to develop the confidence to move forward and advance my dental implant career.

I continued with my education and, like you, had a series of mentors to thank who were at my side pointing me down the path. I remember **Dr. Burt Balkin** finishing at the main podium and approaching me. I was a total stranger. I was in the back of the room. With a handshake he welcomed me to the Academy. He advised, not suggested, that I take the exam. I just listened and said, “Yes.” I guess I never stopped saying “yes,” and I encourage all of you to do the same!

Ultimately, I sat for the AAID and ABOI credential exams. I owe Terry Reynolds, who sadly passed away last year, as well as all my mentors, a debt of gratitude. That’s my history. It may sound familiar to your story as well.

In my heart I believe that the AAID is the very best place to call your implant home. It’s a priority to ensure that we all work together, so as we say in Atlanta, “ya’ll” feel this way as well!

One of my personal goals as President for this year is simple. I’d like to leave our organization in a forward direction, each day a little bit better for all members. Continuing in our tradition of providing the best educational opportunities, I’d like to see our MaxiCourse® growth continue. We now have an incredible 19 operating in 21 different locations. Through the standardization of procedures, protocols and curriculum, they reflect our philosophy and the AAID brand. This consistency is what future students will value, and instills pride that they will be part of, what I consider to be “the preeminent dental implant organization in the world.”

My second goal, I am helping to spearhead and moving forward an inch this year, maybe a foot next year, then yards, and hopefully miles in the future, is obtaining needed recognition by the public for the AAID. As mentioned earlier, we have engaged a marketing firm to raise public awareness of the AAID and the importance of our credentials.

A third goal is specialty status, which brings me to Dr. Frank Recker. He has worked on our behalf for 25 years, before many in this room even became a dentist. He has collaborated with 25 AAID presidents, the American Dental Association, the ABOI, the American Board of Dental

Specialties, the states of Florida, California and Texas, where we won three times! This is a remarkable result. Dr. Recker continues to work toward achieving the AAID’s goal of attaining specialty status.

Frank, when we cross that finish line, we all know it will be because of your sleepless nights, endless travel, courtroom appearances and your passion for our AAID.

On behalf of our Academy, thank you, Dr. Recker!

Juggling all the “balls in the air” this year is our new Executive Director, Cheryl Parker. We all welcome her to her first Annual Conference. She’s articulate, organized, and has a passion for her position. Cheryl demonstrates the leadership qualities necessary in order to guide and drive the Academy forward for years to come. I welcome the opportunity to work closely with her, as well as the Executive Committee and Board of Trustees, to help accomplish our goals. In February, we’ll work to implement a new Strategic Plan for the Academy.

We have more than 5,000 members, money in the bank and an exciting future. This just doesn’t happen. The saying “It takes a village to raise a child” is equally true with an organization. It’s the efforts, large and small, of many, some of whom I’ve already acknowledged. Some others who are responsible for our successes are:

Afshin Alavi, who has graced this Academy with his presence for 21 years and officially retired on Sept. 29. When he arrived, the Academy’s financial stability was in question. However, the good news is he is leaving us in the best financial position ever.

His fiscal policies, along with his attention to every detail, deserve our thanks and gratitude. He understood that as a nonprofit we take seriously the obligations to handle your dues and all revenue in a fiscally responsible and transparent manner.

His accomplishments for the AAID will carry us successfully into the future. Afshin, although you were unable to be here today, we know where you live and have your phone number! So, enjoy your retirement, but that’s not to say your phone won’t ring!

I look forward to working with his successor, our new Director of Finance, William Rohe. He hit the ground running and has transitioned nicely into his new position.

I am also fortunate to work with an executive committee who are all on the same page, and a Board of Trustees that understands the needs of our Academy and are dedicated to our success.

Dr. Natalie Wong, I am proud to be part of an Academy who will have you as our first female and first international President. I can’t think of a better-qualified person to fill those shoes. Did I say shoes? We know how much you like

shoes! The AAID looks forward to being in your very capable hands. We know by the time you're done, you'll leave the AAID with "big shoes to fill!"

Dr. Bernee Dunson, my buddy from down the block. Both Bernie and I practice in midtown Atlanta on Peachtree Street, just one block away from each other. Having a fellow AAID line officer, and a friend courtesy of the AAID so close by, has led to many dinners at local establishments. He is a seasoned veteran, both as a dentist and an officer, who provides dedicated leadership to the AAID. I can bounce ideas off of him and have him look me in the eye and say, "David, you want to do what?"

Dr. Adam Foleck joined the Executive Committee in 2016 as Secretary. I quickly discovered that he was the person we need to help provide the executive leadership to move our marketing campaign forward. He is a savvy practitioner and a natural when it comes to marketing.

Dr. Brian Jackson our new secretary will fit right in. He has a hard working attitude and passion for the Academy. Welcome aboard!

Dr. Richard Mercurio, who served as our Immediate Past President this year, has just completed a six-year, line officer commitment to the AAID. We certainly thank you for all you have done for our Academy.

I want to recognize the AAID team in Chicago, who does an exceptional job on behalf of us all. Thank you so much for your hard work on the behalf of the entire membership.


A final acknowledgement goes out to, **Drs. Joe Orrico** and **Larry Bush**, who had confidence in me, and placed my name for nomination as a line officer on two separate occasions. This is a great example of "if at first you don't succeed, try, try, again."

And I'm appreciative that Joe and Larry did! I thank you, both.

For 67 years we, at the AAID, have grown on the shoulders of those who have come before us — every president, all the members of the Board of Trustees, all the line officers and of course the membership. It is because of their hard work that we are here today, next year in Dallas, the following year in Las Vegas, and then in Bernie's and my home, Atlanta, Georgia.

I am both humbled and honored to become the 65th president of the American Academy of Implant Dentistry. It is a responsibility that I take seriously and embrace. I pledge to you that I will strive to move the Academy forward in its efforts to educate dentists, as well as its efforts to educate the public about the AAID. We will let them know how our skills can enhance them both.

After all, it's all about the patient.

Thank you, so very much. Let's have a great year! 



Show your AAID PRIDE

Order your AAID logo scrubs

<https://glsgroupinc.com/aaid>





By Richard A. Guaccio,
DDS, F-RET, DABOI/ID

How Times Have Changed

EDITOR'S NOTE: *The AAID News has added a new column — “Then and Now,” to be written by a different AAID past president. It will include a comparison of the issues facing the Academy and implant dentistry when the past president served in office with what is happening in the profession and the AAID today. Our first contributor is **Dr. Richard A. Guaccio** who served as AAID president 1989-90. Any past president who wishes to contribute an article should send it by email to editor@aid.com.*

Some historical perspective is in order: I placed my first implant in 1971 and joined the AAID in 1974. I was elected to the AAID presidency in 1989-90.

When I assumed the position of president we were still operating out of a three person office in Boston, Massachusetts. While that office was sufficient for the early years, it was not designed for achieving the goals of our constitution and bylaws. The ultimate goal of achieving specialty status for implant dentistry demanded a larger office and professional staff.

We closed that office and went on to work with a professional management company (Slack Incorporated). **Dr. Paul Schnitman** proposed Slack and it was certainly a move in the right direction. This led to moving our headquarters to the ADA building in Chicago where it has prospered. We employed counsel in Washington D.C. to help us prepare for specialty recognition and although we believed we met all the requirements for specialty status the ADA Council on Dental Education did not and we were turned down.

We continued on that mission and during my presidency we activated the American Board of Oral Implantology/ Implant Dentistry (ABOI/ID) in 1990 and gave the first exam at the ADA building. It was a great feeling of accomplishment that the ABOI/ID board members and I felt.

With the creation of the American Board of Dental Specialties (ABDS) and the great strides that our legal counsel has made in getting our bona fide credentials accepted, I believe implant dentistry has made remarkable progress. From blades and subperiosteals (which are still performed today) to single tooth implants systems and the “all on four” technique, we are now helping millions of people around the world gain function and esthetics.

In the beginning, there were no formal implant training programs and we learned at seminars that may have lasted one day. Today thanks to the recognition by the AAID that formal educational programs were needed, the Academy launched the MaxiCourse® programs. Our members



President of the American Academy of Implant Dentistry – 1989-90

were instrumental in these endeavors and these member-driven courses have met with great success.

We know that implant dentistry involves both surgery and prosthetics and training beyond dental school. It pains me to see dentists advertising in newspapers, direct mail and on their office signs that they perform implant dentistry when they are only performing one aspect of the

discipline. That is not to say that there are not specialists in other disciplines that can only do one aspect of implant dentistry. They offer a great service to our profession. However, I believe there should be a distinction made in advertising between implant prosthetics and implant surgery. Would it not be the same as advertising braces, root canals and extractions but then referring those patients somewhere else? We have evolved to the point where such distinction can be made.

Implant dentistry has been the “hottest thing going” in dentistry for more the 30 years. One need only look at all the publications in dentistry to see that if not for implants there would be almost no advertising.

We are in a perfect place with the ABOI/ID and the

Implant dentistry has been the “hottest thing going” in dentistry for more the 30 years.

ABDS to gain the respect of the professions and earn specialty recognition.

The number of new applicants for AAID credentials and the large number of those sitting for the didactic and experiential components of the ABOI/ID exam give testimony to our validity. I am equally impressed by the many from existing specialties that are seeking our credentials.

To realize that a discipline that was begun by general dentists is well on its way to specialty recognition is indeed heartwarming. Thank you to the many pioneers who persevered and helped make this moment happen.

I will close by telling you a true story when I began performing implant dentistry in 1971. A local dental specialist told people that I was “killing people and causing cancer.” My how times have changed!!

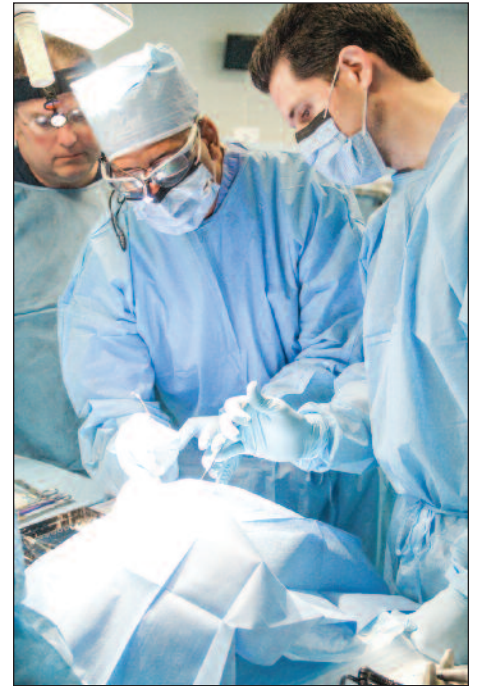
Dr. Richard Guaccio, of Crown Point, Indiana, is an Honored Fellow of the AAID and a Diplomate of the ABOI/ID. He was awarded the Aaron Gershkoff/Norman Goldberg Award in 2012.

Washington D.C. (Mid-Atlantic) MaxiCourse[®]

Thirty years ago, AAID Past President, **Dr. Terry J. Reynolds**, developed the concept of quality comprehensive education, to prepare practicing dentists for training in the field of dental implantology. At that time, his thoughts were that a series of “mini courses” would make up a curriculum that was substantially more comprehensive and entitled it “MaxiCourse[®].” This trailblazing MaxiCourse[®] concept has proven to be a significant cornerstone of the American Academy of Implant Dentistry’s mission to provide quality, comprehensive implant education. The Academy now has twenty such programs throughout North America and around the world.

Years ago, one such program existed in Washington D.C. at Howard University. The AAID is proud to announce that the Washington D.C. (Mid-Atlantic) MaxiCourse[®] is being reestablished at Howard University. The “Washington D.C. (Mid-Atlantic) MaxiCourse[®]” program, unlike before will now contain a clinical/surgical component. The program will not just be “educational” (didactic), but also an “experience” (surgical/clinical component), providing a more practical learning journey. Each participant will have the opportunity to perform live surgeries under direct supervision on their patients. In addition, the program includes enriched hands-on laboratory procedures and an entire module with a focus on implant dentistry in the digital world.

The redesigned program also uses an online platform called Dental Campus, which is an innovative educational effort to provide well-structured



Hands-on experience will be offered at the Washington, DC (Mid-Atlantic) AAID MaxiCourse[®].

supplemental education in implant dentistry utilizing modern web technology. This program also includes self-assessment protocols for the students and enables interactive communication within the learning community. The mission of the D.C. MaxiCourse[®] is to provide each participant the opportunity to incorporate their enriching experience into their practice in a predictable, practical and profitable manner.

The director of the program is **Berne C. Dunson, DDS, FAAID, DABOI/ID**. Joining him as clinical co-directors are **C. Benson Clark, DDS, FAAID, DABOI/ID** and **Adam Kimowitz, DDS, AFAAID, DABOI/ID**. The D.C.

MaxiCourse® or “Capital Max” has strategically assembled a strong group of outstanding diplomates as faculty to provide our participants with a wealth of knowledge from their vast years of experience. The course not only provides graduating students with the 300 hours required to qualify for AAID Associate Fellow written exam, but also positions them favorably to challenge the Oral Case/Part 2 examination for credentialing as well.

The D.C. MaxiCourse® will be offered at Howard University’s School of Dentistry with two of the 10 sessions being held at the Future Dental Center in Pennsylvania. The program commences March 2018, with graduation scheduled for December 2018. Registration and additional information can be obtained online by visiting www.dcmmaxicourse.com, emailing dcmmaxi@dunsondental.com or calling Mrs. Keonka Williams at 404-897-1699.



Howard University will be the site of the Washington, D.C. (Mid-Atlantic) AAID MaxiCourse®.

University at Buffalo, The State University of New York Clinical Assistant or Associate Professor (HS), Assistant or Associate Professor (HS)

The Department of Restorative Dentistry, School of Dental Medicine at the University at Buffalo is seeking applicants for a full-time faculty position concentrating in Implant Dentistry. Major responsibilities include: pre-clinical and clinical teaching of implant prosthodontics and surgery at pre- and post-doctoral level. Position is full-time, clinical or tenure-track. Faculty rank is commensurate with teaching experience.

Must have DDS, DMD or equivalent degree; 2) Must be eligible for licensure in New York State; 3) Post-Graduate training in CODA approved program in Periodontology, or Prosthodontics, or Implant Dentistry Certificate Program. Completion of a 2 year Advanced Education in General Dentistry or foreign equivalent combined with an Implantology Post-Graduate Program may also qualify; 4) Completion of Part I and Part II of National Dental Board Examination; 5) Completed implant training or credentials from ABOI, AAID or ICOI will be considered.

Tenure-track applicants must also present evidence of scholarly activity and an established independent research program.

Salary and rank are commensurate with the candidate’s qualifications and experience. A faculty practice opportunity is available for NYS licensed individuals.

All applications must be completed on-line at the following website (posting #F1700147)

<http://www.ubjobs.buffalo.edu/postings/11474>

The University at Buffalo is an Equal Opportunity/Affirmative Action Employer/Recruiter.

UB **University at Buffalo**
The State University of New York

AAID FOUNDATION AWARDS MORE THAN \$80,000 IN GRANTS

The AAID Foundation awarded over \$80,000 to four research teams to help them continue their work in dental implant-specific research. The Foundation has now provided nearly \$1 million in research funding since the inception of the Foundation's Endowment Fund.



University of Parma (Italy) — Dr. Guido Macaluso: **Bioactive Printed Substitute for Bone Regeneration — Preclinical Study**

The University of Hong Kong (Hong Kong) — Dr. Christie Lung Ying Kei: **New Antibacterial Mesoporous Bioactive Glass Coating on Titanium**

Oregon Health & Science University (United States) — Dr. Luiz E. Bertassoni: **Dual-Ink 3D Printing of Pre-Vascularized Scaffolds for Vertical Bone Augmentation**

Tufts University School of Dental Medicine (United States) — Dr. Yumi Ogata: **Comparison of Dimensional Changes in Peri-implant Buccal Bone and Soft Tissue in Grafted and Native Bone: A Prospective Clinical Study in Humans**

SUMMARY OF ACTIONS TAKEN BY BOARD OF TRUSTEES

October 10, 2017, San Diego, California

APPROVED 2017-2018 Committee Appointments

RECOGNIZED graduation from a full-time periodontal, oral and maxillofacial surgery, or prosthodontics

program as fulfilling Associate Fellow and Fellow education requirements

GRANTED one-year extension to 2018 for credentialed members who had not attended an Annual Conference in past three years

APPROVED Life Membership for **Dr. Alfred Fellman** effective January 1, 2018

ESTABLISHED selection criteria for the Terry Reynolds Trailblazer Award and appointed committee

AUTHORIZED investment in an international educational program in Auckland, New Zealand in late 2018 or early 2019

ADOPTED the 2018 Budget

CONGRATULATIONS TO JAMES RUTKOWSKI, DMD, PHD

Dr. James Rutkowski of Clarion, PA won a drawing for the free 2018 AAID membership dues. He was selected in the drawing of those who referred a new member to the Academy between November 1, 2016 and October 31, 2017. Any member who refers a new member is entered into the annual drawing. The more referrals you make, the more entries you receive.



WITH NON-OPIOID EXPAREL



CHANGE THE FACE OF POSTSURGICAL RECOVERY

Your patients are concerned about opioids. Based on a recent survey, **>75%** of oral surgery patients and caregivers would opt for non-opioid pain management if given the choice even at additional cost (n=1370).¹

Choose EXPAREL:
New data vs bupivacaine HCl from a total knee arthroplasty study^{2*}

78% FEWER OPIOIDS

overall opioid consumption ($P<0.005$)

13.6% LESS PAIN

cumulative pain scores ($P<0.04$)

**10% OF PATIENTS WERE
OPIOID FREE WITH EXPAREL VS 0%
WITH BUPIVACAINE HCl ($P<0.01$)**

*Results from a Phase 4, double-blind, randomized controlled trial that compared the efficacy and safety of EXPAREL 266 mg (20 mL) (n=70) and bupivacaine HCl (n=69) in a total knee arthroplasty. Primary endpoints: area under the curve of visual analog scale pain intensity scores 12–48 hours postsurgery; total opioid consumption 0–48 hours postsurgery. Rescue opioids for pain were available upon patient request. Rates and types of adverse events were similar between treatment groups. The most common adverse events in the EXPAREL group were nausea, muscle spasms, and vomiting.

The clinical benefit of the decrease in opioid consumption has not been demonstrated.

EXPAREL is indicated for administration into the surgical site to produce postsurgical analgesia.

Important Safety Information

EXPAREL is contraindicated in obstetrical paracervical block anesthesia. In clinical trials, the most common adverse reactions (incidence $\geq 10\%$) following EXPAREL administration were nausea, constipation, and vomiting. EXPAREL is not recommended to be used in the following patient population: patients <18 years old and/or pregnant patients. Because amide-type local anesthetics, such as bupivacaine, are metabolized by the liver, EXPAREL should be used cautiously in patients with hepatic disease. Patients with severe hepatic disease, because of their inability to metabolize local anesthetics normally, are at a greater risk of developing toxic plasma concentrations.

Warnings and Precautions Specific to EXPAREL

EXPAREL is not recommended for the following types or routes of administration: epidural, intrathecal, regional nerve blocks, or intravascular or intra-articular use. Non-bupivacaine-based local anesthetics, including lidocaine, may cause an immediate release of bupivacaine from EXPAREL if administered together locally. The administration of EXPAREL may follow the administration of lidocaine after a delay of 20 minutes or more. Formulations of bupivacaine other than EXPAREL should not be administered within 96 hours following administration of EXPAREL.

Warnings and Precautions for Bupivacaine-Containing Products

Central Nervous System (CNS) Reactions: There have been reports of adverse neurologic reactions with the use of local anesthetics. These include persistent anesthesia and paresthesias. CNS reactions are characterized by excitation and/or depression. **Cardiovascular System Reactions:** Toxic blood concentrations depress cardiac conductivity and excitability which may lead to dysrhythmias sometimes leading to death. **Allergic Reactions:** Allergic-type reactions (eg, anaphylaxis and angioedema) are rare and may occur as a result of hypersensitivity to the local anesthetic or to other formulation ingredients. **Chondrolysis:** There have been reports of chondrolysis (mostly in the shoulder joint) following intra-articular infusion of local anesthetics, which is an unapproved use.

Please see brief summary of Prescribing Information on adjacent page. Full Prescribing Information is also available at www.EXPAREL.com.

References: 1. McCormick S, Franco P. Patient attitudes toward opioids and nonopioid alternatives following third-molar extraction. Poster presented at: ACOMS 37th Annual Scientific Conference and Exhibition, May 2017; Vancouver, British Columbia. 2. Mont MA, Beaver WB, Dysart SH, Barrington JW, Del Gaizo DJ. Local infiltration analgesia with liposomal bupivacaine improves pain scores and reduces opioid use after total knee arthroplasty: results of a randomized controlled trial [published online ahead of print]. *J Arthroplasty*. doi:10.1016/j.arth.2017.07.024.

For more information, please visit www.EXPAREL.com or call 1-855-RX-EXPAREL (793-9727).

PACIRA
PHARMACEUTICALS, INC.

©2017 Pacira Pharmaceuticals, Inc., Parsippany, NJ 07054 PP-EX-US-2959 09/17

EXPAREL
(bupivacaine liposome injectable suspension)

OPIOID FREE

EXPAREL®

(bupivacaine liposome injectable suspension)

Brief Summary

(For full prescribing information refer to package insert)

INDICATIONS AND USAGE

EXPAREL is indicated for administration into the surgical site to produce postsurgical analgesia.

EXPAREL has not been studied for use in patients younger than 18 years of age.

CONTRAINDICATIONS

EXPAREL is contraindicated in obstetrical paracervical block anesthesia. While EXPAREL has not been tested with this technique, the use of bupivacaine HCl with this technique has resulted in fetal bradycardia and death.

WARNINGS AND PRECAUTIONS

Warnings and Precautions Specific for EXPAREL

As there is a potential risk of severe life-threatening adverse effects associated with the administration of bupivacaine, EXPAREL should be administered in a setting where trained personnel and equipment are available to promptly treat patients who show evidence of neurological or cardiac toxicity.

Caution should be taken to avoid accidental intravascular injection of EXPAREL. Convulsions and cardiac arrest have occurred following accidental intravascular injection of bupivacaine and other amide-containing products.

Using EXPAREL followed by other bupivacaine formulations has not been studied in clinical trials. Formulations of bupivacaine other than EXPAREL should not be administered within 96 hours following administration of EXPAREL.

EXPAREL has not been evaluated for the following uses and, therefore, is not recommended for these types of analgesia or routes of administration.

- epidural
- intrathecal
- regional nerve blocks
- intravascular or intra-articular use

EXPAREL has not been evaluated for use in the following patient population and, therefore, it is not recommended for administration to these groups.

- patients younger than 18 years old
- pregnant patients

The ability of EXPAREL to achieve effective anesthesia has not been studied. Therefore, EXPAREL is not indicated for pre-incisional or pre-procedural loco-regional anesthetic techniques that require deep and complete sensory block in the area of administration.

ADVERSE REACTIONS

Clinical Trial Experience

The safety of EXPAREL was evaluated in 10 randomized, double-blind, local administration into the surgical site clinical studies involving 823 patients undergoing various surgical procedures. Patients were administered a dose ranging from 66 to 532 mg of EXPAREL. In these studies, the most common adverse reactions (incidence greater than or equal to 10%) following EXPAREL administration were nausea, constipation, and vomiting.

The common adverse reactions (incidence greater than or equal to 2% to less than 10%) following EXPAREL administration were pyrexia, dizziness, edema peripheral, anemia, hypotension, pruritus, tachycardia, headache, insomnia, anemia postoperative, muscle spasms, hemorrhagic anemia, back pain, somnolence, and procedural pain.

DRUG INTERACTIONS

EXPAREL can be administered in the ready to use suspension or diluted to a concentration of up to 0.89 mg/mL (i.e., 1:14 dilution by volume) with normal (0.9%) saline or lactated Ringer's solution. EXPAREL must not be diluted with water or other hypotonic agents as it will result in disruption of the liposomal particles.

EXPAREL should not be admixed with local anesthetics other than bupivacaine. Non-bupivacaine based local anesthetics, including lidocaine, may cause an immediate release of bupivacaine from EXPAREL if administered together locally. The administration of EXPAREL may follow the administration of lidocaine after a delay of 20 minutes or more.

Bupivacaine HCl administered together with EXPAREL may impact the pharmacokinetic and/or physicochemical properties of EXPAREL, and this effect is concentration dependent. Therefore, bupivacaine HCl and EXPAREL may be administered simultaneously in the same syringe, and bupivacaine HCl may be injected immediately before EXPAREL as long as the ratio of the milligram dose of bupivacaine HCl solution to EXPAREL does not exceed 1:2.

The toxic effects of these drugs are additive and their administration should be used with caution including monitoring for neurologic and cardiovascular effects related to toxicity.

Other than bupivacaine as noted above, EXPAREL should not be admixed with other drugs prior to administration.

USE IN SPECIFIC POPULATIONS

Pregnancy

Risk Summary

There are no studies conducted with EXPAREL in pregnant women. In animal reproduction studies, embryo-fetal deaths were observed with subcutaneous administration of bupivacaine to rabbits during organogenesis at a dose equivalent to 1.6 times the maximum recommended human dose (MRHD) of 266 mg. Subcutaneous administration of bupivacaine to rats from implantation through weaning produced decreased pup survival at a dose equivalent to 1.5 times the MRHD [see Data]. Based on animal data, advise pregnant women of the potential risks to a fetus.

The background risk of major birth defects and miscarriage for the indicated population is unknown. However, the background risk in the

U.S. general population of major birth defects is 2-4% and of miscarriage is 15-20% of clinically recognized pregnancies.

Clinical Considerations

Labor or Delivery

Bupivacaine is contraindicated for obstetrical paracervical block anesthesia. While EXPAREL has not been studied with this technique, the use of bupivacaine for obstetrical paracervical block anesthesia has resulted in fetal bradycardia and death.

Bupivacaine can rapidly cross the placenta, and when used for epidural, caudal, or pudendal block anesthesia, can cause varying degrees of maternal, fetal, and neonatal toxicity. The incidence and degree of toxicity depend upon the procedure performed, the type, and amount of drug used, and the technique of drug administration. Adverse reactions in the parturient, fetus, and neonate involve alterations of the central nervous system, peripheral vascular tone, and cardiac function.

Data

Animal Data

Bupivacaine hydrochloride was administered subcutaneously to rats and rabbits during the period of organogenesis (implantation to closure of the hard plate). Rat doses were 4.4, 13.3, and 40 mg/kg/day (equivalent to 0.2, 0.5 and 1.5 times the MRHD, respectively, based on the BSA comparisons and a 60 kg human weight) and rabbit doses were 1.3, 5.8, and 22.2 mg/kg/day (equivalent to 0.1, 0.4 and 1.6 times the MRHD, respectively, based on the BSA comparisons and a 60 kg human weight). No embryo-fetal effects were observed in rats at the doses tested with the high dose causing increased maternal lethality. An increase in embryofetal deaths was observed in rabbits at the high dose in the absence of maternal toxicity.

Decreased pup survival was noted at 1.5 times the MRHD in a rat pre- and post-natal development study when pregnant animals were administered subcutaneous doses of 4.4, 13.3, and 40 mg/kg/day buprenorphine hydrochloride (equivalent to 0.2, 0.5 and 1.5 times the MRHD, respectively, based on the BSA comparisons and a 60 kg human weight) from implantation through weaning (during pregnancy and lactation).

Lactation

Risk Summary

Limited published literature reports that bupivacaine and its' metabolite, pipercolylxylidide, are present in human milk at low levels. There is no available information on effects of the drug in the breastfed infant or effects of the drug on milk production. The developmental and health benefits of breastfeeding should be considered along with the mother's clinical need for EXPAREL and any potential adverse effects on the breastfed infant from EXPAREL or from the underlying maternal condition.

Pediatric Use

Safety and effectiveness in pediatric patients have not been established.

Geriatric Use

Of the total number of patients in the EXPAREL surgical site infiltration clinical studies (N=823), 171 patients were greater than or equal to 65 years of age and 47 patients were greater than or equal to 75 years of age. No overall differences in safety or effectiveness were observed between these patients and younger patients. Clinical experience with EXPAREL has not identified differences in efficacy or safety between elderly and younger patients, but greater sensitivity of some older individuals cannot be ruled out.

Hepatic Impairment

Because amide-type local anesthetics, such as bupivacaine, are metabolized by the liver, these drugs should be used cautiously in patients with hepatic disease. Patients with severe hepatic disease, because of their inability to metabolize local anesthetics normally, are at a greater risk of developing toxic plasma concentrations.

Renal Impairment

Bupivacaine is known to be substantially excreted by the kidney, and the risk of toxic reactions to this drug may be greater in patients with impaired renal function. Care should be taken in dose selection of EXPAREL.

OVERDOSAGE

In the clinical study program, maximum plasma concentration (C_{max}) values of approximately 34,000 ng/mL were reported and likely reflected inadvertent intravascular administration of EXPAREL or systemic absorption of EXPAREL at the surgical site. The plasma bupivacaine measurements did not discern between free and liposomal-bound bupivacaine making the clinical relevance of the reported values uncertain; however, no discernible adverse events or clinical sequelae were observed in these patients.

DOSAGE AND ADMINISTRATION

EXPAREL is intended for single-dose administration only.

The recommended dose of EXPAREL is based on the following factors:

- Size of the surgical site
- Volume required to cover the area
- Individual patient factors that may impact the safety of an amide local anesthetic
- Maximum dose of 266 mg (20 mL)

As general guidance in selecting the proper dosing for the planned surgical site, two examples of dosing are provided. One example of the recommended dose comes from a study in patients undergoing bunionectomy. A total of 8 mL (106 mg) was administered as 7 mL of EXPAREL infiltrated into the tissues surrounding the osteotomy, and 1 mL infiltrated into the subcutaneous tissue.

Another example comes from a study of patients undergoing hemorrhoidectomy. A total of 20 mL (266 mg) of EXPAREL was diluted with 10 mL of saline, for a total of 30 mL, divided into six 5 mL aliquots, injected by visualizing the anal sphincter as a clock face and slowly infiltrating one aliquot to each of the even numbers to produce a field block.

Compatibility Considerations

Admixing EXPAREL with drugs other than bupivacaine HCl prior to administration is not recommended.

- Non-bupivacaine based local anesthetics, including lidocaine, may cause an immediate release of bupivacaine from EXPAREL if administered together locally. The administration of EXPAREL

may follow the administration of lidocaine after a delay of 20 minutes or more.

- Bupivacaine HCl administered together with EXPAREL may impact the pharmacokinetic and/or physicochemical properties of EXPAREL, and this effect is concentration dependent. Therefore, bupivacaine HCl and EXPAREL may be administered simultaneously in the same syringe, and bupivacaine HCl may be injected immediately before EXPAREL as long as the ratio of the milligram dose of bupivacaine HCl solution to EXPAREL does not exceed 1:2.

The toxic effects of these drugs are additive and their administration should be used with caution including monitoring for neurologic and cardiovascular effects related to toxicity.

- When a topical antiseptic such as povidone iodine (e.g., Betadine®) is applied, the site should be allowed to dry before EXPAREL is administered into the surgical site. EXPAREL should not be allowed to come into contact with antiseptics such as povidone iodine in solution.

Studies conducted with EXPAREL demonstrated that the most common implantable materials (polypropylene, PTFE, silicone, stainless steel, and titanium) are not affected by the presence of EXPAREL any more than they are by saline. None of the materials studied had an adverse effect on EXPAREL.

Non-Interchangeability with Other Formulations of Bupivacaine

Different formulations of bupivacaine are not bioequivalent even if the milligram dosage is the same. Therefore, it is not possible to convert dosing from any other formulations of bupivacaine to EXPAREL and vice versa.

CLINICAL PHARMACOLOGY

Pharmacokinetics

Local infiltration of EXPAREL results in significant systemic plasma levels of bupivacaine which can persist for 96 hours. Systemic plasma levels of bupivacaine following administration of EXPAREL are not correlated with local efficacy.

CLINICAL STUDIES

The efficacy of EXPAREL was compared to placebo in two multicenter, randomized, double-blinded clinical trials. One trial evaluated the treatments in patients undergoing bunionectomy; the other trial evaluated the treatments in patients undergoing hemorrhoidectomy.

Study 1

A multicenter, randomized, double-blind, placebo-controlled, parallel-group clinical trial evaluated the safety and efficacy of 106 mg (8 mL) EXPAREL in 193 patients undergoing bunionectomy. The mean age was 43 years (range 18 to 72).

Study medication was administered directly into the site at the conclusion of the surgery, prior to closure. There was an infiltration of 7 mL of EXPAREL into the tissues surrounding the osteotomy and 1 mL into the subcutaneous tissue.

Pain intensity was rated by the patients on a 0 to 10 numeric rating scale (NRS) out to 72 hours. Postoperatively, patients were allowed rescue medication (5 mg oxycodone/325 mg acetaminophen orally every 4 to 6 hours as needed) or, if that was insufficient within the first 24 hours, ketorolac (15 to 30 mg IV). The primary outcome measure was the area under the curve (AUC) of the NRS pain intensity scores (cumulative pain scores) collected over the first 24 hour period. There was a significant treatment effect for EXPAREL compared to placebo. EXPAREL demonstrated a significant reduction in pain intensity compared to placebo for up to 24 hours (p<0.001).

Study 2

A multicenter, randomized, double-blind, placebo-controlled, parallel-group clinical trial evaluated the safety and efficacy of 266 mg (20 mL) EXPAREL in 189 patients undergoing hemorrhoidectomy. The mean age was 48 years (range 18 to 86).

Study medication was administered directly into the site (greater than or equal to 3 cm) at the conclusion of the surgery. Dilution of 20 mL of EXPAREL with 10 mL of saline, for a total of 30 mL, was divided into six 5 mL aliquots. A field block was performed by visualizing the anal sphincter as a clock face and slowly infiltrating one aliquot to each of the even numbers.

Pain intensity was rated by the patients on a 0 to 10 NRS at multiple time points up to 72 hours. Postoperatively, patients were allowed rescue medication (morphine sulfate 10 mg intramuscular every 4 hours as needed).

The primary outcome measure was the AUC of the NRS pain intensity scores (cumulative pain scores) collected over the first 72 hour period. There was a significant treatment effect for EXPAREL compared to placebo.

This resulted in a decrease in opioid consumption, the clinical benefit of which was not demonstrated.

Twenty-eight percent of patients treated with EXPAREL required no rescue medication at 72 hours compared to 10% treated with placebo. For those patients who did require rescue medication, the mean amount of morphine sulfate intramuscular injections used over 72 hours was 22 mg for patients treated with EXPAREL and 29 mg for patients treated with placebo.

The median time to rescue analgesic use was for 15 hours for patients treated with EXPAREL and one hour for patients treated with placebo.

Pacira Pharmaceuticals, Inc.
San Diego, CA 92121 USA

Patent Numbers:

6,132,766 5,891,467
5,766,627 8,182,835

Trademark of Pacira Pharmaceuticals, Inc.

PACIRA
PHARMACEUTICALS, INC.

For additional information call 1-855-RX-EXPAREL (1-855-793-9727)

Rx only

August 2016

MEMBER AMBASSADORS

AAID Membership Ambassadors know firsthand how membership in the Academy helps dentists establish or expand their expertise in implant dentistry and encourage their colleagues to join the AAID.

We would like to thank the Membership Ambassadors who have referred colleagues as new members between September 13, 2017 and December 4, 2017.

Thank you for referring three colleagues to the Academy:

Michael Wehrle, DDS from Hurst, TX

Thank you for referring a colleague to the Academy:

Jim Amstadt, DDS, from Eagle River, WI

Dr. Mohammad Al Attas, from Riyadh, Saudi Arabia

Ronald A. Bryant, DDS, MSD, from Seattle, WA

Danny Domingue, DDS, from Lafayette, LA

Mike Freimuth, DDS, from Wheatridge, CO

Rob Heller, DDS, from Lewis Center, OH

Andrew Ingel, DMD, from Las Vegas, NV

Shankar Iyer, DDS, MDS, from Elizabeth, NJ

Brian Jackson, DDS, from Utica, NY

Steve Johns, DDS, from Cookeville, TN

Chad Lewison, DDS, from Canton, SD

Encourage your colleagues to join the AAID and offer them a \$50 discount on their first year's membership dues by letting us know you referred them. Do so by November 1, 2018, and be entered into a drawing for 2019 AAID membership dues — up to a \$600 value.

If you would like to request membership applications to share with colleagues, contact the Headquarters Office at info@aaid.com or by phone at 312-335-1550.

2017 FOUNDATION AUCTION PARTICIPANTS

The AAID Foundation raised more than \$100,000 — a new record thanks in large part to the AAID MaxiCourses® — at its auction held during AAID's 2017 Annual Educational Conference in San Diego last October.

The Foundation thanks the following individuals and organizations that donated items for the auction.

MaxiCourse® Donors

Asia MaxiCourse®:

Shankar Iyer, DDS, MDS

Chicago Midwest

MaxiCourse®: **Natalie Wong, DDS & Adam Foleck, DMD**

Georgia MaxiCourse®:

Douglas Clepper, DMD & Michael Pruett, DMD

Las Vegas MaxiCourse®:

John Minichetti, DMD

Loma Linda University

MaxiCourse®: **Jaime Lozada, DMD**

New York MaxiCourse®:

John Minichetti, DMD

Oregon MaxiCourse®:

S. Shane Samy, DMD

TexMax Implant

MaxiCourse®: **Jay Elliott, DDS**

Ti-Max Institute

MaxiCourse®: **George Arvanitis, DDS & Roderick Stewart, DDS**

Vancouver

MaxiCourse®: **William Liang, DMD**

Washington, DC (Mid-Atlantic)

MaxiCourse®: **Bernee Dunson, DDS**

Other Dental

Education Courses

Donors

ABOI/ID

Dental Implant Learning Center

Hybridge

KAT Impants

Meisinger USA

Pikos Institute

Clinical and Practice Donors

Augma Biomaterials USA
CareCredit

Ceatus Media Group

Consult-PRO

Glidewell Laboratories

Impladent Ltd.

Laschal Surgical

Instruments

Nobel Biocare USA

Osstell

Osteogenics Biomedical

Quintessence

Publishing Co.

Rocket Mountain Tissue

Bank

Salvin Dental

Specialties, Inc.

Versah

Vacation Donors


Hyatt Regency Dallas

DENTISTRY TODAY

Dozens of members of the American Academy of Implant Dentistry were included in the listing of the 20th Annual Leaders in CE report featured in the December 2017 issue of *Dentistry Today*.

Several including Drs.

Thomas Balshi, **Gordon Christensen, Ed Kusek, Tim Kosinski, Robert Miller, Craig Misch, Justin Moody, Paresh Patel, Michael Pikos, Jack Piermatti, Michael Tischler, and Natalie Wong** were featured on the cover.



UPCOMING KEY AAID DATES

FEBRUARY 2018

1 APPLICATION DEADLINE FOR ASSOCIATE FELLOW PART 2 AND FELLOW EXAMINATIONS

2-4 ABOI/ID BOARD REVIEW COURSE

Chicago, IL

APRIL 2018

13-15 ABOI/ID EXAMINATION

Chicago, IL

20-21 FOCUS ON THE SINUS 2.0

Newport Beach, CA

28-30 PART 2/ORAL CASE EXAM

Chicago, IL

JUNE 2018

8-9 DECODING DIGITAL DENTISTRY

Washington, D.C.

SEPTEMBER 2018

26-29 67TH ANNUAL IMPLANT DENTISTRY EDUCATION CONFERENCE

Hyatt Regency Dallas, Dallas, TX

Check the AAID online calendar using this QR Code for a complete listing of all key AAID dates. ●



AAID MEMBERS IN THE NEWS



Michael Tischler, DDS, FAAID, DABOI/ID, of Woodstock, NY, was featured on Spectrum News of Hudson Valley in a

two-and-a-half minute news video about his donation of implant dental work for a two-tour Vietnam Veteran. The patient — whose nickname is “Smiley” — can now truly be proud of his smile after the six-month process to provide him with a new set of teeth.



John Minichetti, DDS, FAAID, DABOI/ID, of Englewood, NJ, was appointed Chief of Dentistry at the

Englewood Hospital and Medical Center.



Mike Freimuth, DDS, AFAAID, DABOI/ID, of Wheatridge, CO had an article entitled, “Clinical Digital Photography” published in the October/November 2017 issue of *Implant Practice US*.



The late **Leonard Linkow, DDS, FAAID, DABOI/ID**, and a past president of the AAID along with recently deceased honorary member Jack Wimmer will be memorialized and honored in an implant section of the Venice, Italy, museum of medicine.



An article entitled, “The Whole Package: Taking Patients from Implant Restorations in a Multidisciplinary practice,” by **David Little, DDS**, was published in the October/November 2017 issue of *Implant Practice US*.



Justin Moody, DDS, FAAID, DABOI/ID had an article entitled, “Systems-driven Dental Implant Practice” published in the October/November 2017 issue of *Implant Practice US*. ●



IMMEDIATE STABILITY.



You choose when to load. Immediate. Progressive. Or Delayed.

Call 800-228-0477 to learn more.

AAID Very Visible at GNYDM

The American Academy of Implant Dentistry played a major role at the 2017 Greater New York Dental Meeting's World Implant Expo. In addition to having a booth in the exhibit hall, the Academy educated over 75 dentists who were interested in implant dentistry at four different programs, including two lectures and two hands-on workshops.

AAID's programs included:

- Implant Prosthodontics: A Step-by-Step Approach presented by **Natalie Wong, DDS, Cert Prosthodontics, FAAID, DABOI/ID**

- Sinus Augmentation Techniques presented by **Joseph Leonetti, DMD, FAAID, DABOI/ID**
- Prevention and Management of Dental Implant Complications presented by **Bart Silverman, DMD, DABOI/ID**
- Sinus Grafting with and without Implant Placement presented by **John C. Minichetti, DMD, FAAID, DABOI/ID**

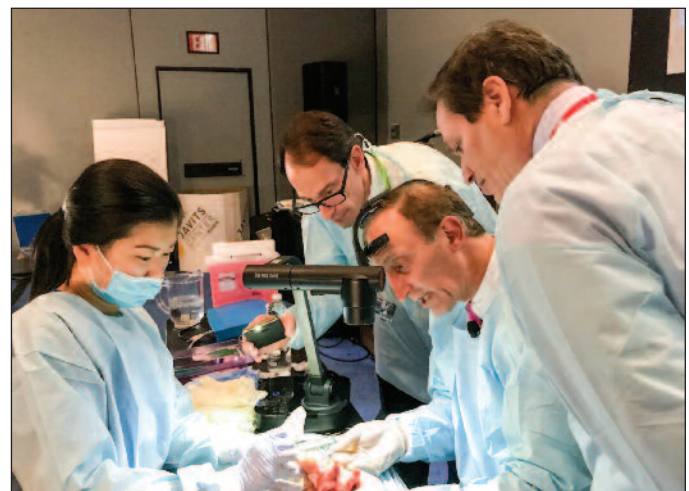This marked the third year the AAID has participated as both an exhibitor and primary educator about implant dentistry. The Academy will again have a significant presence at the 2018 Greater New York Dental Meeting, which will be held November 23 – 28, 2018, at the Jacob K. Javits Convention Center in New York City.



A packed classroom watched as the instructor demonstrated a technique during one of AAID's hands-on sessions at the 2017 Greater New York



Drs. Bart Silverman (from left), Kirk Kalogiannis and John Minichetti chat on the exhibit floor of the Implant World Expo.



Attendees at AAID's courses not only learned by doing but received expert training as well.

Annual AAID Business Meeting Summary

The 2017 Annual Business Meeting of the American Academy of Implant Dentistry was called to order by **President Shankar Iyer** at 2:15 pm at the Hilton San Diego Bayfront on October 13, 2017. A quorum was present.

Following is a summary of the activities, actions, and reports at the meeting:

- Inducted 80 new Associate Fellow members and 24 new Fellows
- Introduced six new credentialed members as the 2017 Class of Honored Fellows
- Observed a moment of reflection in memory of the following members who had been reported as having passed away since the 2016 Annual Business Meeting:
 - **Andre Buchs**, Orlando, FL
 - **Kiritkumar Salvi**, Corona, CA
 - **Leonard Linkow**, Fort Lee, NJ, AAID President 1974, Gershkoff recipient 1974, Isaih Lew winner 1990
 - **Carl Misch**, Miami Beach, FL, AAID President 1993, Gershkoff recipient 1999, Isaih Lew 1998.
 - **Jack Wimmer**, Honorary Member



Dr. David Hochberg talked about why it's all about the patient in his speech at the AAID Annual Business Meeting.



Dr. David Hochberg presented outgoing president Dr. Shankar Iyer with a plaque and Past President's pin.

- President Iyer reviewed the highlights and changes at the Academy during the 2017 year, including progress in getting AAID credentials recognized in several states and adding new MaxiCourses®, both in the U.S. and abroad during 2017
- Dr. Richard Mercurio, chair of the Nominating Committee reported that no further nominations had been received, so the slate of officers for 2017 was elected as follows:
 - President:
Dr. David Hochberg
 - President-Elect:
Dr. Natalie Wong
 - Vice President:
Dr. Bernee Dunson
 - Treasurer:
Dr. Adam Foleck
 - Secretary:
Dr. Brian Jackson

The following reports were delivered:

- The 2017 Annual Conference report by **Dr. John Minichetti** reported that 980 doctors attended the meeting, making it the highest doctor attendance for a meeting at a non-Las Vegas location. The 2017 meeting also broke the record for most concurrent courses with 28

hands-on courses held during the three-and-a-half days of education.

- Treasurer, **Dr. Bernee Dunson** reported that the Academy is in very good financial shape. He invited members who wanted a copy of the financial statements to send a request to William Rohe, the AAID Director of Finance.
- Dr. Frank Recker updated the assembly of changes since the 2016 Annual Business Meeting. In June, the 5th Circuit United States Court of Appeals upheld the lower court's decision in our Texas lawsuit thus adding Louisiana and Mississippi to Texas as the states in which ABOI/ID Diplomates can be recognized as specialists.
- **Dr. Arthur Molzan**, president of the American Board of Oral Implantology/Implant Dentistry, reported that a record number of 39 new Diplomates were certified in 2017, bringing the total number to 497 Diplomates, 415 of whom are active.
- Chair of the AAID Foundation, **Dr. Bernee Dunson** reported that the Foundation noted that the AAID Foundation total assets grew to over \$4 million. The Foundation awarded eight student research grants of \$2,500 each for a total of \$20,000 and will be awarding larger grants of \$25,000 each in the Fall.
- **Dr. David Hochberg** recognized President Iyer for his leadership of the Academy and presented him a Plaque of Appreciation and the Past President's pin.
- Dr. Hochberg delivered his inaugural address which can be found in its entirety beginning on page 32 of this issue of *AAID News*.
- The Business Meeting adjourned at 3:55 p.m. ●

NEODENT[®] Symposium 2018 DANA POINT CALIFORNIA

Reimagining your implant practice - Success for Tomorrow Starts Today

This is the perfect opportunity to stay current on the latest treatment techniques while enjoying time with colleagues in a beautiful resort environment.

Our speakers will cover the hottest topics in implant dentistry including: digital workflow, immediate loading, tissue regeneration, esthetics and full arch solutions.



Dr. Geninho Thome



Dr. Sergio Rocha Bernardes



Dr. R. Brinks Austin



Dr. Carlos Araujo



Dr. Mark Adams



Dr. Alex Molinari



Dr. Jonathan Abenaim



Dr. Daniel F. Galindo



Dr. Caesar C. Butura



Mr. Antonio Corradini



Mr. Enrico Steger

Held at the Ritz-Carlton Laguna Niguel. This luxury resort offers world-class accommodations and spa services, and is nestled on the cliffs above Laguna Beach. Seating is limited, reserve your seat today.



JUNE 8 & 9, 2018 • DANA POINT CALIFORNIA

NEODENT[®]
A Straumann Group Brand

To register contact your local
Neodent representative or visit
us at: www.neodent.us/symposium

Focus On the Sinus 2.0

Expand your surgical knowledge...Enhance patient outcomes

AAID's Western District will present Focus on the Sinus 2.0, April 19 – 21, 2018, where you will experience two days of concentrated education on sinus augmentation procedures — past, present and future.

Hear exciting new developments on how to approach maxillary sinus grafting for predictable results.

Learn new techniques to minimize complications while grafting the maxillary sinus.

View real clinical scenarios during one of our three live surgical demonstrations showcasing the latest methods and maxillary sinus grafting procedures.

Help honor **Dr. Carol Phillips** for her accomplishments on behalf of the AAID, the Western District and implant dentistry.

Registration and detailed information is available at aaid.com/western2018.

On Thursday, April 19, 2018, there will be a Corporate Forum as well as hands-on workshops. Friday and Saturday, April 20 – 21, 2018, will include lectures as well as three live surgeries that will be broadcast from various surgical suites as they happen. Live commentary from the surgeon will be featured.

Friday and Saturday will offer the following programs:

A Conversation with the Father of the Sinus Lift

O. Hilt Tatum, Jr., DDS, FAAID, DABOI/ID

Jaime L. Lozada, DMD, FAAID, DABOI/ID

An ENT's Perspective on the Maxillary Sinus

Christopher Church, MD
Evolution of Maxillary Sinus Graft
Dennis G. Smiler, DDS, MScD, AFAAID

Live Surgery Broadcast from Loma Linda University Sinus Graft: Lateral Approach

Surgeon: **Aladdin Al-Ardah, DDS, MS, FAAID, DABOI/ID**

Moderator: Pascal Valentini, DDS

Live Surgery Broadcast from Loma Linda University Sinus Graft Endoscopic Crestal Approach

Surgeons: Christopher Church, MD, and **Jaime Lozada, DMD, FAAID, DABOI/ID**

Moderator: **Nicholas Caplanis, DMD, MS, FAAID, DABOI/ID**

Intra-Operative Complications

Pablo Galindo-Moreno, DDS, PhD

Prevention and Management of Post-Operative Complications

Pascal Valentini, DDS

Is there a Role of Autogenous Bone in Sinus Grafts?

Craig M. Misch, DDS, MDS, FAAID, DABOI/ID

10 Game-Changers I have Learned Over the Past 30 Years

Stephen S. Wallace, DDS

Efficient Lateral Access to the Maxillary Sinus

Surgeon: **Nicholas Caplanis, DMD, MS, FAAID, DABOI/ID**

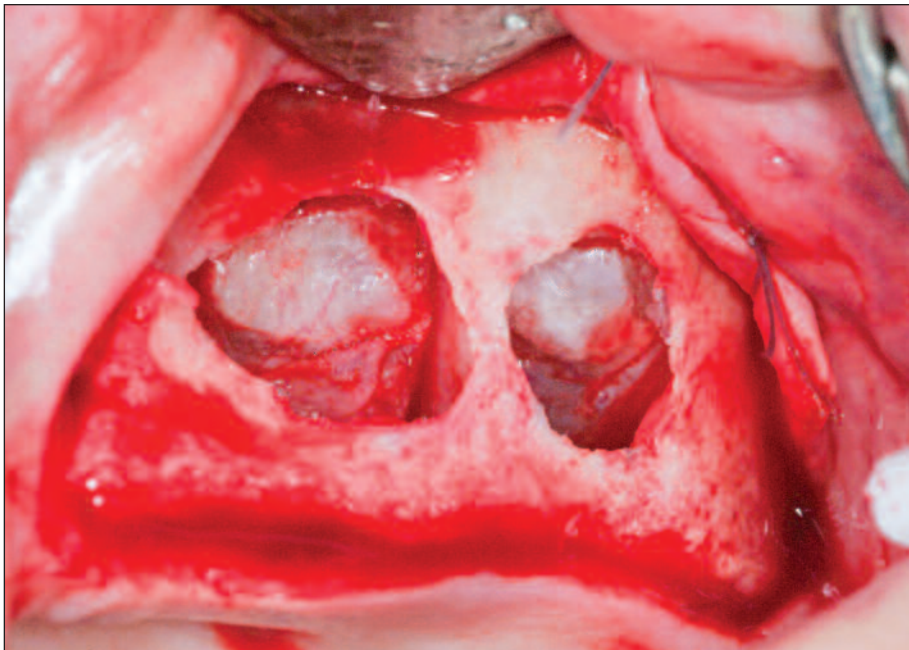Moderator: **Jaime Lozada, DDS, FAAID, DABOI/ID**

Implant Placement in the Low Sinus: Paradigm Shift-From Lateral Approach to Osseodensification

Ziv Mazor, DMD

Sinus Grafts: What am I doing today?

Ole T. Jensen, DDS, MS



In depth learning, both didactic and participatory, await attendees at Focus on the Sinus 2.0.

No Two Patients are the Same



We Provide the Widest Selection of Restorative Components and Support for ALL Your Implant Patients!


REMOVABLE OPTIONS



Locator



Clix Ball Implant Abutment



R-Tx

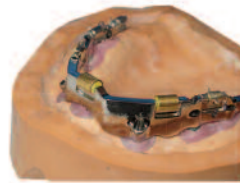
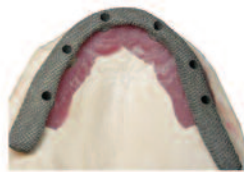
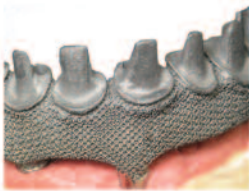
O-Ring Implant Abutment



Shiner Magnet

PRISM PRINTED BAR OPTIONS



Selective Laser Melting with the Accuracy of 5-Axis CNC Milling


FIXED OPTIONS



F-Tx



Multi-Unit Abutment



Ti Base



Esthetic Abutment

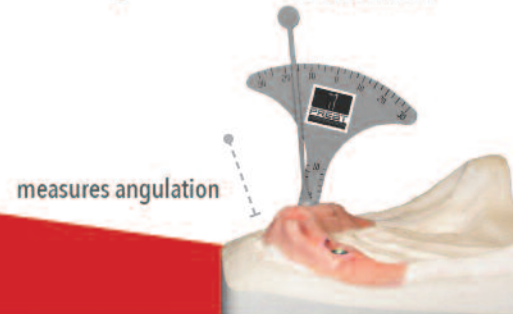
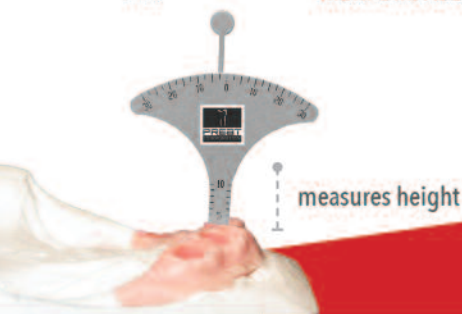
Verification Cylinder



UCLA Abutment

FEATURED PRODUCTS Cuff Height and Angulation Tool Set



The
MUST HAVE TOOL
FOR IMPLANT PROFESSIONALS!

We have the expertise to help you on your first Locator prosthesis or your most challenging Fixed Detachable restoration. Count on PREAT parts and expertise.

Contact PREAT at 1-800-232-7732 • www.PREAT.com

Dental Implant World Joined the AAID in San Diego

A record number of dentists from around the world attended the AAID's 66th Annual Education Conference held in San Diego this past October. Thirty-two different countries were represented. One highlight was a full-day of presentations by clinicians



Dr. Iyer surprised the audience at the President's Celebration by wandering through the crowd conducting interviews with new and old friends at the dinner.



The delegation from the India MaxiCourse® recognized Dr. Iyer and his wife, Preeti, with a traditional ceremony that is done in India to honor a great teacher.

from a dozen different countries at AAID's inaugural Leonard Linkow Memorial Global Symposium.

The conference was attended by nearly 1,700 total attendees who learned from the top experts in implant dentistry, over three-and one-half days. A record 28 hands-on workshops and 11 limited attendance seminars supplemented 20 hours of main podium presentations. Streaming media from the main podium presentations is available for purchase online at aaid.com.

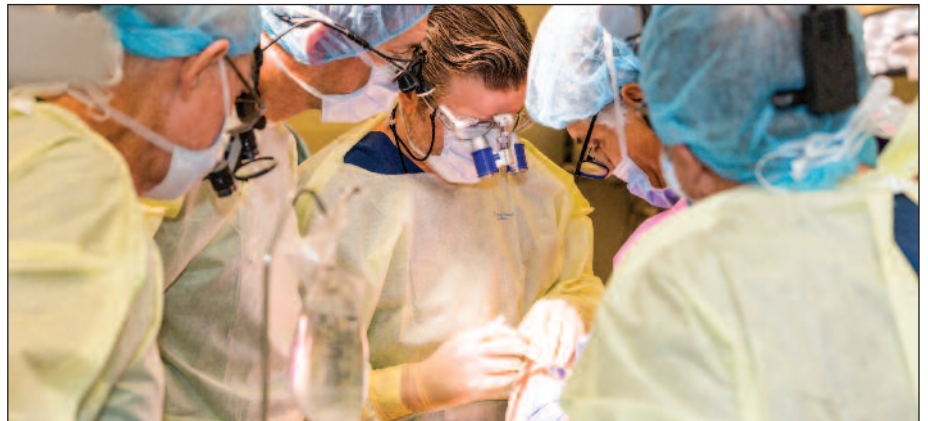The broadcast of two live surgeries with simultaneous commentary from the surgeon, and the opportunity for attendees to ask questions during the

procedure was available again this year.

Be sure to join your colleagues at AAID's 67th Annual Education Conference, September 26 – 29, 2018, in Dallas, Texas.



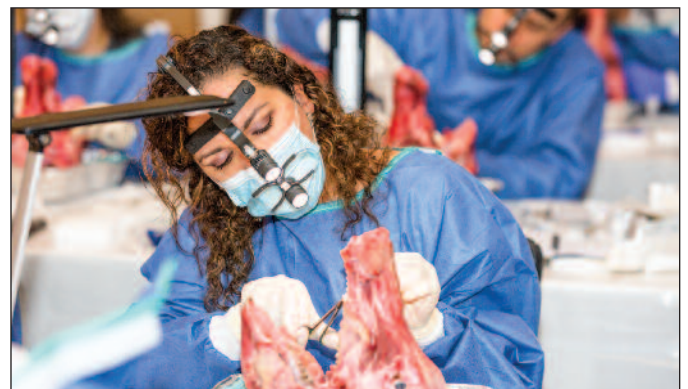Table clinics were popular for personalized learning at AAID's Annual Conference.



A full-day hands-on course on cadaver heads allowed attendees to learn hard and soft tissue techniques during the Annual Conference.

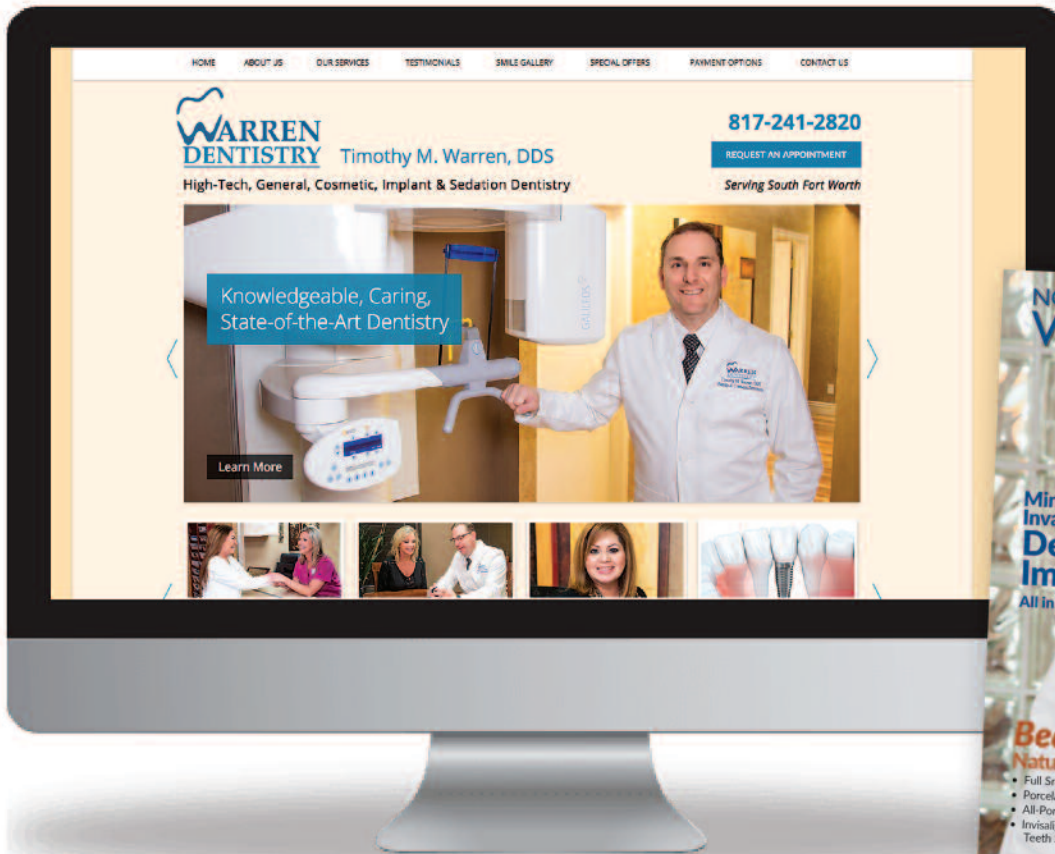

High energy performances by Karmagraphy, an acclaimed Bollywood dance troupe was a highlight of the President's Celebration.



Hands-on courses are a hallmark of the AAID Annual Conference and scientific programs. A record number of 28 hands-on courses were available.

We focus on **Dental Implant Marketing** for any type of practice.



For the last decade we have been helping practices successfully market dental implants. Over the years we have developed our marketing to:

- Target the right demographics for implant cases in any area.
- Successfully obtain implant cases, including full-mouth cases.
- Help overcome patient objections on cost. Our marketing is designed to “pre-sell” the prospective patient.

FREE MARKETING CONSULTATION FOR AAD MEMBERS

with Dental Marketing Expert Keith Gilleard
President of Gilleard Dental Marketing



GILLEARD DENTAL MARKETING

info@gilleardmarketing.com

(855) 486-2410

www.GilleardDentalMarketing.com

© 2017-2018 Gilleard Marketing.

Down Syndrome doesn't keep Andrew Down

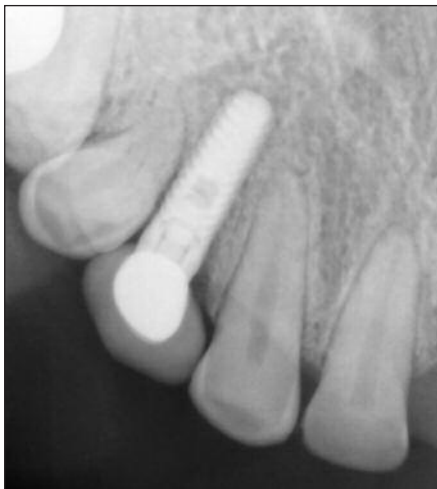Despite having Down Syndrome and Autism Spectrum Disorder, Andrew is a 24-year-old, self-taught artist and poet who also works part-time at his local Target. He has been able to maintain healthy oral hygiene and has never had a cavity. However, his two top teeth never grew in causing him bite and speech issues.

Unable to afford the necessary treatment, Andrew's general dentist recommended that he and his mother apply to the Wish-a-Smile Program created by the American Academy of Implant Dentistry Foundation. This

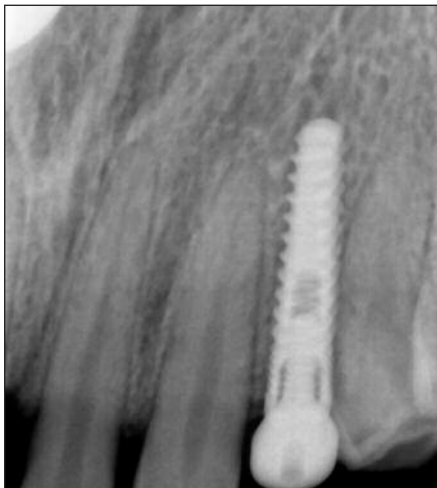program arranges for free dental implant services to those who are congenitally missing teeth.

Dental Lifeline, the national organization that works with the AAID Foundation to help administer the program, contacted **Dr. John Minichetti**, a Fellow of the AAID and Diplomate of the American Board of

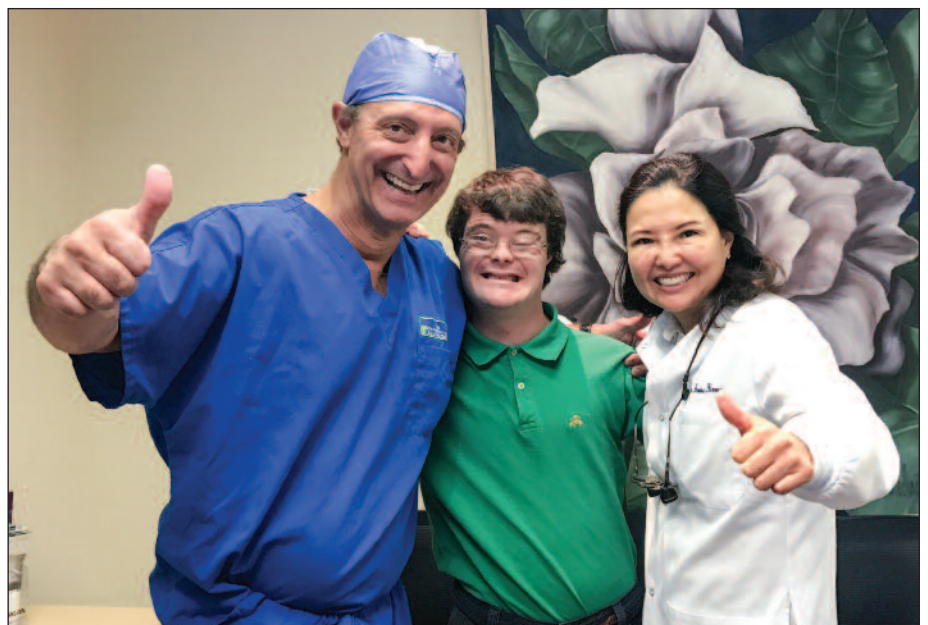Oral Implantology/Implant Dentistry. Andrew met with Dr. Minichetti at his Englewood, New Jersey, dental office for an initial consultation. After a thorough examination, Dr. Minichetti recommended a treatment plan that included placing implants in the maxilla to replace teeth #6 and #11 that were congenitally missing.



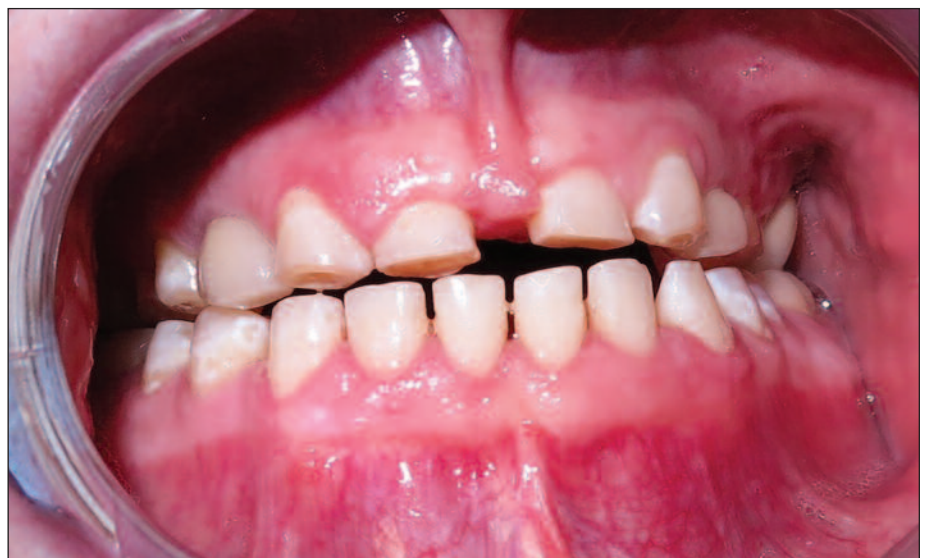The implant placed by Dr. Minichetti in tooth #6.



The implant placed by Dr. Minichetti in tooth #11.



Andrew (center) with Dr. Minichetti and Dr. Anna Hong share their smiles after the treatment.



Andrew's full set of teeth after treatment.

Through the AAID Foundation's Wish-a-Smile program, Dr. Minichetti replaced the two missing teeth at no charge to Andrew or his family.

The treatment was successful and a few weeks after completion, a package arrived at Dr. Minichetti's office marked "personal." In the large envelope was a book with photos of some of Andrew's artwork, including several from juried art shows, and some of his poetry. He wrote, "Your interest in helping me brought a smile to my face

"We are thrilled that Andrew was able to have life altering dental treatment at no cost through the AAID Foundation Wish-a-Smile program," said **Dr. Bernee Dunson**, president of the AAID Foundation. "In addition to providing treatment to those who are congenitally missing teeth, the Wish-a-Smile Program also helps financially

disadvantaged, disabled veterans who are missing teeth," he added.

Dr. Minichetti and his entire staff were deeply moved by Andrew's gift

and note of appreciation. Andrew's passion for art, poetry and life could now be seen on the outside through his new smile. ●

Volunteer or refer a patient to Wish-a-Smile

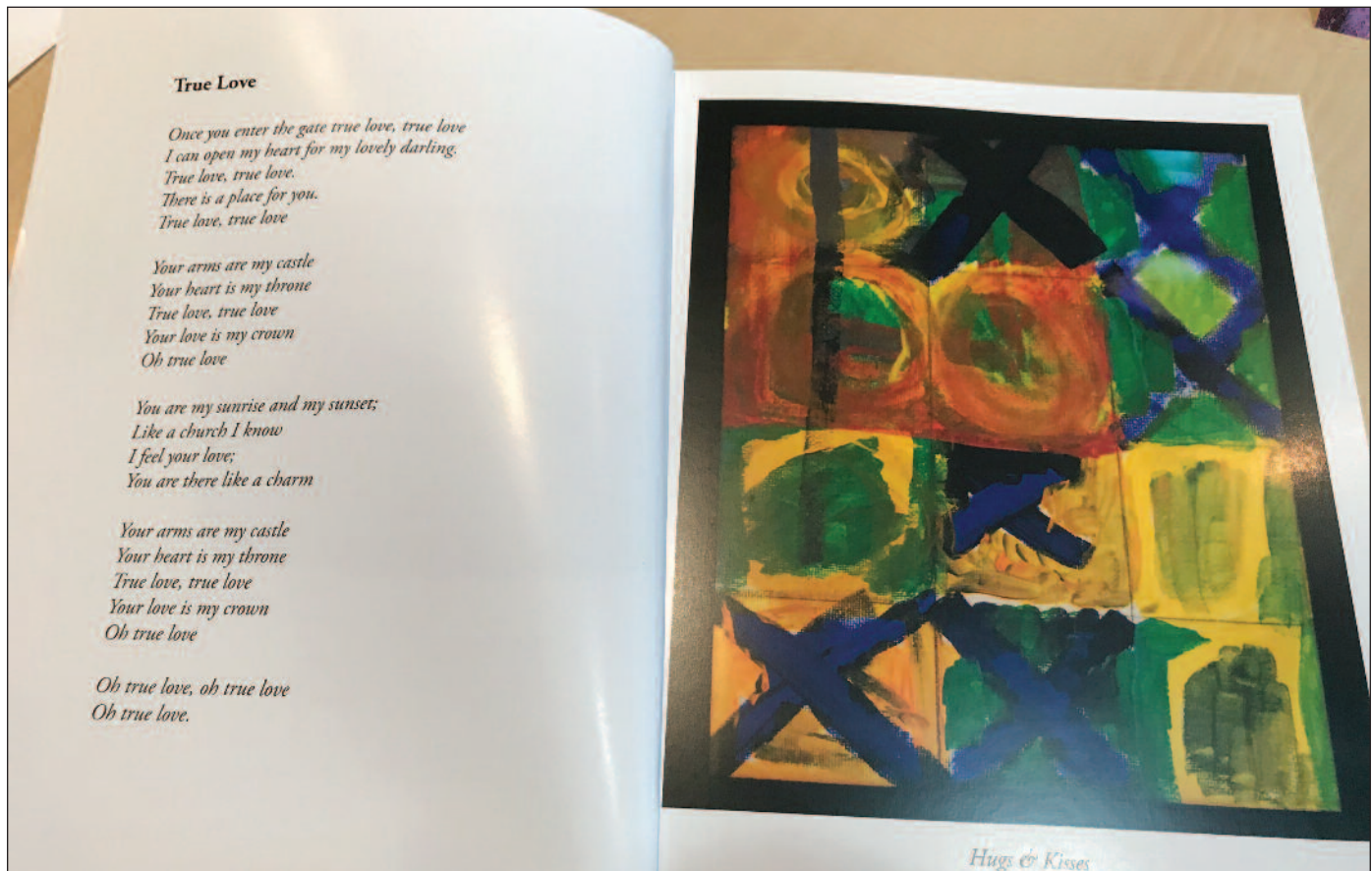
This nationwide program provides free dental service to the following:

- Disabled veterans who are financially disadvantaged patients — age 17 and older with 1 – 3 missing teeth
- Patients, 17 and older, who are congenitally missing 1 – 3 teeth and are financially disadvantaged
- Disabled veterans who are financially disadvantaged 17 and older who are edentulous or have terminal dentition to a 2-implant overdenture solution

The Foundation and Dental Lifeline Network will seek donations from labs and manufacturers of needed restorative supplies and services, as well as the implants.

Refer a patient: Call 1-877-827-1284

Volunteer or donate to Wish-a-Smile: aaid.com/foundation



2017 AAID Associate Fellows



Benjamin Jaret Aanderud, DMD, Sherwood, OR, earned a dental degree from Oregon Health and Science University in 1998. He is also a graduate of the 2014 Oregon MaxiCourse®.



Karen Baghdasaryan, DDS, Glendale, CA, obtained a dental degree from Yarevan State Medical University in 1994.



Shyam Subrahmanya Bhat, BDS, MDS, Mangalore, Karnataka, India, received a dental degree from AB Shetty Memorial Institute of Dental Sciences in 2009 and also finished the Oral Maxillofacial Surgery program at the AB Shetty Memorial Institute in 2013. Dr. Bhat completed the 2015 Asia MaxiCourse®.



Frank A. Caputo, DDS, Racine, WI, is a 2011 graduate of Marquette University, School of Dentistry and a graduate of the 2015 Las Vegas MaxiCourse®.



Nasser M. Alqahtani, BDS, MSD, Loma Linda, CA, received a dental degree in 2009 from King Khalid University and a Master of Science in Dentistry from Indiana University in 2016. Dr. Alqahtani is a 2017 graduate of the Implant Dentistry Fellowship program at Loma Linda University.



Prithvi Balepur, BDS, MDS, Bangalore, Karnataka, India, received his dental degree from the AB Shetty Memorial Institute of Dental Sciences in 2004 and his second degree from Saveetha Dental College in 2008. Dr. Balepur is a graduate of the 2013 Asia MaxiCourse®.



Christopher Blair, DDS, Oakville, ON, Canada, earned a dental degree from the University of Toronto in 1993. In 2015, he completed AAID's TI-MAX Institute MaxiCourse®.



Dr. Joey Chen, Taipei, Taiwan, earned his dental degree at Northwestern University in 2001 and completed a program in Prosthodontics at the University of California at San Francisco in 2004.



Motoyasu Atsumi, DDS, Shizuoka-ken, Japan, earned his dental degree from the University of Hokkaido in 1995 and completed the Japan MaxiCourse® in 2016.



Zachary Becroft, DDS, Sioux Falls, SD, completed his dental degree at the University of Minnesota in 2009 and the Las Vegas MaxiCourse® in 2013.



Devin Mikael Brice, DMD, North Bend, OR, received a dental degree from Oregon Health and Science University in 2008. In 2011, he completed the Oregon MaxiCourse®.



Irbad Chowdhury, DMD, North Aurora, IL, earned a dental degree from Southern Illinois University in 2010.

[see AAID Fellows p. 56](#)

Washington D.C. (Mid-Atlantic) Maxicourse

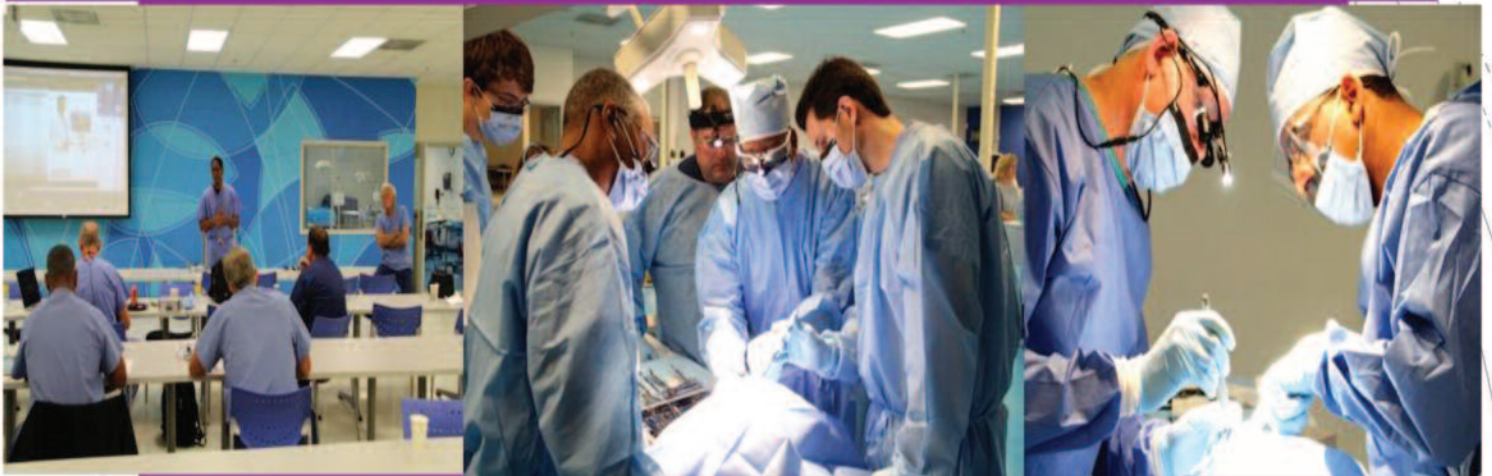

Classes Begin
March 2018

Register Now



The D.C. Maxicourse® prepares the participants to take the written portion of the AAID Associate Fellow Examination and provides the 300+ hours necessary to fulfill the CE requirement of the AAID Associate Fellow process.



For more information please visit our website at dcmaxicourse.com or contact our Administrator, **Mrs. Keonka Williams** 404-897-1699 DCMAXI@dunsondental.com

**Dr. Bernee C. Dunson, Director
AAID, Vice President**



**Howard University
School of Dentistry**

Approved PACE Program Provider FAGD/MAGD Credit Approval does not imply acceptance by a state or provincial board of dentistry or AGD endorsement. June 1, 2014 to May 31, 2018.



AAID Fellows

continued from p. 54



Richard Ryan Conkle, DDS, Laguna Hills, CA, received a dental degree in 2004 from the University of Southern California. He continued his education in the U.S. Navy where he completed the Advanced Education in General Dentistry program in 2005.



Minal Satyen Desai, BDS, Riverbank, CA, received a dental degree from Dav Centenary College (India) in 1998 and completed the 2014 Las Vegas MaxiCourse®.



Josee Desrochers, Verdun, QC, Canada, attended the Universite de Montreal where she earned her dental degree in 1989.



Michael Doe, DMD, Harrisonburg, VA, received a dental degree from Boston University in 2008.



Chinedu John Ezeji-Okoye, DDS, Calgary, AB, Canada, earned a dental degree from University of California at San Francisco in 1997.



Brad Fulkerson, DMD, Amesburg, MA, is a 2007 graduate of Tufts University School of Dental Medicine.



Wai Kee Fung, DDS, Greenwood Lake, NY, earned a dental degree from New York University in 1999.



Masafumi Furuhashi, DDS, Nagoya-shi, Aichi-ken, Japan, received a dental degree from Aichi Gakuin University in 2003. Dr. Furuhashi is a graduate of the 2015 Japan MaxiCourse®.



Riyaz Gangji, DDS, Bethlehem, PA, completed his dental degree at Ohio State University in 1992 and a residency program at Miami Valley Hospital the following year. He trained in implant dentistry at the 2016 Rutgers University MaxiCourse®.



Chris Gauquie, DDS, Greenville, NC, earned a dental degree from Virginia Commonwealth University in 1999 and is a graduate of the 2013 Georgia MaxiCourse®.



Brendan John Hallissey, DMD, Kittery, ME, is a 2006 graduate from University of Connecticut School of Dental Medicine. In 2015, he completed the Puerto Rico MaxiCourse®.



May Ayad Hamid, MSC, Abu Dhabi, United Arab Emirates, earned a dental degree from Ajman University in 2008 and received a Masters in Science in Oral Surgery/Implantology from Maktoum bin Hamdan Dental University College in 2016. She is also a graduate of the 2014 Asia MaxiCourse®.



Mitra Hashemi, DDS, Sidney, BC, Canada, received her dental degree in 2008 from the University of Western Ontario. Dr. Hashemi completed the Vancouver MaxiCourse® in 2016.



Gene Allen Herrera, DDS, Concord, CA, graduated from the University of Pacific, Arthur A. Dugoni School of Dentistry in 2003.



Madhavi Kaluskar, DDS, North Brunswick, NJ, earned her dental degree in 2000 from New York University.



Dr. Byunggyu Kim, ChunAn City, ChungNam, South Korea, received a dental degree from Dankook University in 2013. He later completed the AAID's Korea MaxiCourse® in 2016.



Gyutae Lee, MSD, Cheonan-si, Chungcheongnam-do, South Korea, earned both of his dental degrees from Yonsei University Dental College in 2009 and 2012. Dr. Lee also completed the 2016 Korea MaxiCourse®.



J. Eric Hopkins, DDS, Shawnee, OK, earned a dental degree from University of Oklahoma in 1989.



Raj Kandola, DDS, Oakville, ON, Canada, graduated from the University of Toronto in 2000 and continued his implant dentistry education by completing the 2013 TI-MAX Institute MaxiCourse®.



Eunbae Kim, DDS, Seoul, South Korea earned a dental degree from Seoul National University in 2010. Dr. Kim finished AAID's Korea MaxiCourse® in 2016.



Gregory Louie, DDS, Danville, CA, earned a dental degree in 1986 from University of Pacific, Arthur A. Dugoni School of Dentistry. In 2004, he completed the Prosthodontics program at the University of Illinois at Chicago.



Scott Hudimac, DDS, Latrobe, PA, is a 1990 graduate of West Virginia University, School of Dentistry.



Noozhan Karimi, DDS, MSC, Loma Linda, CA, completed the Oral Implantology/Implant Dentistry program at Loma Linda University in 2017.



Rana Koussayer, DDS, Jeddah, Saudi Arabia, received her dental degree in 1988 from Aleppo University and is a graduate of the 2014 Asia MaxiCourse®.



Joseph Gerard McCartin, DDS, Chicago, IL, completed his dental degree in 1984 at Marquette University. He is also a graduate of the Las Vegas MaxiCourse® class of 2014.



Tomomi Ito, DDS, PhD, Gifu-shi, Gifu-Ken, Japan, received both dental degrees from Asahi University in 1987 and 1995. She also completed the Japan MaxiCourse® in 2016.



Sophan Kay, DDS, Tucson, AZ, is a 2000 graduate of the Marquette University School of Dentistry and completed the Loma Linda MaxiCourse® in 2012.

[see AAID Fellows p. 58](#)

AAID Fellows

continued from p. 57



Richard Allen McKinney Jr., DMD, Sherwood, OR, earned a dental degree in 2010 from the Oregon Health and Science University and later completed a residency at the Naval Hospital Portsmouth in 2011. He graduated from the AAID's 2014 MaxiCourse® held in Oregon.



Priyanka Mishra, BDS, Mumbai, Maharashtra, India, received a dental degree from Chatrapati Shahu Maharaj Shikshan Sanstha Dental College in 2008. Dr. Mishra is a graduate of the 2014 Asia MaxiCourse®.



Rushitum Mistry, BDS, MDS, Mumbai, Maharashtra, India, received his dental degrees from Government Dental College (Mumbai) in 1988 and the University of Pittsburgh in 1992. In 2015, he completed the 2015 Asia MaxiCourse®.



Saiesha Mistry, BDS, Mumbai, Maharashtra, India, completed a dental degree at Government Dental College and Hospital (Mumbai) in 1991 and a residency at Eastman Dental Hospital in 1994. She is a 2013 graduate of the Asia MaxiCourse®.



Atef Ismail Mohamed, BDS, MDS, Cairo, Egypt, received his dental degree from Cairo University in 1986.



ChauLong Thi Nguyen, DDS, Menlo Park, CA, earned her dental degree from the University of Pacific in 2000. In 2002, she finished the Advanced Education in General Dentistry program at the University of California at San Francisco. Dr. Nguyen is a graduate of Loma Linda MaxiCourse® class of 2015.



Pierre Obeid, DDS, Leamington, ON, Canada, is a 1996 graduate of the University of Detroit Mercy School of Dentistry and completed the 2014 TI-MAX Institute MaxiCourse®.



Harmohinder Kaur Oberoi, BDS, DMD, Edison, NJ, completed her dental degree at Fairleigh Dickinson University in 1990.



Rand Russell Ollerton, DDS, Half Moon Bay, CA, earned a dental degree from Virginia Commonwealth University in 1984.



Kaneshige Ozawa, DDS, Nagoyas-shi, Aichi-ken, Japan, received a dental degree from Aichi Gakuin University in 2006. He completed the 2016 Japan MaxiCourse®.



Rimmie Pandher, DMD, Modesto, CA, received a dental degree from Boston University in 1996. She later graduated from AAID's 2014 Las Vegas MaxiCourse®.



Purvak Vijay Parikh, DDS, Roseville, CA, earned his dental degree from Government Dental College (Ahmedabad) in 2000.



Rujul Parikh, DDS, Manteca, CA, received his degree in 1997 from Government Dental College (Ahmedabad).



Dongjin Park, DDS, MS, Anyang-si, Gyeonggi-do, South Korea, earned a dental degree from Kyung Hee University in 2014 and is a graduate of the 2015 Korea MaxiCourse®.



Nandan Patel, DDS, Modesto, CA, completed his dental degree at the College of Dental Sciences, India in 2000.



Mohammed Edrees Sayed, BDS, MDS, PhD, Rahway, NJ, received both his dental degree (2013) and PhD (2017) from Rutgers University. Dr. Sayed completed the Surgical Implant Fellowship program at Rutgers University in 2016.



Ryan Sill, DMD, Albuquerque, NM, received his dental degree from Oregon Health and Science University in 2009. In 2010, he finished the Advanced Education in General Dentistry program at University of New Mexico and is a graduate of the 2013 Las Vegas MaxiCourse®.



Prakash Sojitra, DDS, Salida, CA, received a dental degree from the University of Southern California, Los Angeles in 2011.



Ravi Patel, DDS, Chicago, IL, earned his dental degree from Indiana University in 2013 and completed the Las Vegas MaxiCourse® the following year in 2014.



Ishita Shah, DDS, Milpitas, CA, earned her dental degree from the Government Dental College (Ahmedabad) in 2005.



Mario Silvestri, DDS, Vestal, NY, graduated from the University of Buffalo School of Dental Medicine and completed a General Practice Residency at Englewood Hospital in 1990. Dr. Silvestri completed AAID's 2016 Las Vegas MaxiCourse®.



Mohamed Soliman, BDS, DDS, Calgary, AB, Canada, earned a dental degree from University of Toronto in 2008. He continued his dental implant education through the 2014 Las Vegas MaxiCourse®.



Subramaniam Ramkumar, MDS, Chennai, Tamil Nadu, India, attended Rajah Muthiah Dental College where he received his dental degree in 1993 and completed an Oral/Maxillofacial Surgery program in 1998. He also completed the Asia MaxiCourse® in 2012.



Artur Shahnubaryan, DDS, Burbank, CA, received a dental degree from Yerevan State Medical University in Armenia in 1994.



Sonia Kaur Singh, DMD, Warren, MI, graduated from Boston University with a dental degree in 1998.



Kyle Gregory Stanley, DDS, Los Angeles, CA, received a dental degree in 2010 from the University of Southern California.



Victoria Rubinoff, DDS, Woodmere, NY, received a dental degree from New York University in 2005.



Fathima Ayesha Thajudeen, BDS, Sri Lanka, received a dental degree in 2006 at the University of Peradeniya. In 2014, Dr. Thajudeen completed the Asia MaxiCourse®.

[see AAID Fellows p. 60](#)

AAID Fellows

continued from p. 59



Tristan Thompson, DMD, Lexington, KY, received a dental degree from the University of Kentucky in 2012. The following year, he concurrently completed a residency program at Vidant Hospital and the 2013 Georgia MaxiCourse®.



Laura VanDyk, DDS, Sumner, WA, earned a dental degree in 2008 from the University of Washington. Dr. VanDyk also completed the Oregon MaxiCourse® in 2013.



Norma Vazquez, DDS, Riverside, CA, earned a dental degree in 2006 from Loma Linda University and is also a graduate of the 2014 Loma Linda MaxiCourse®.



V. Vijaya, BDS, MDS, Hyderabad, Andhra Pradesh, India, received a dental degree from the Government Dental College and Hospital (Andhra Pradesh) in 1999 and a certificate in periodontics in 2002 from Mahe Institute of Dental Science. Dr. Vijaya is also a graduate of the 2012 Asia MaxiCourse®.



James T. Wong, DDS, Maywood, CA, earned a dental degree from the Institute of Dental Medicine, Myanmar in 1991 and is a 2012 Loma Linda MaxiCourse® graduate.



Taeyoung You, DDS, Gwangmyeong-si, Gyeonggi-do, South Korea, earned his dental degree from the Chosun University Dental College in 2009. Dr. You is a graduate of the 2014 Korea MaxiCourse®.



Mahmood Zaitr, BDS, Clifton, NJ, received his dental degree from New York University in 2001. He also completed the 2016 Rutgers University MaxiCourse®.



3.0 x 6.0mm









4.5 x 6.0mm

THE PROVEN LEADER IN SHORT IMPLANTS

With the Bicon design, edentulous sites with minimal bone can be restored simply—sites which simply could not be restored with other implant designs.

www.bicon.com



4.0 x 5.0mm



6.0 x 5.0mm

2017 AAID Fellows



Mohammed Al Attas, BDS, Riyadh, Saudi Arabia, attained his dental degree from King Abdulaziz University in 2007. Dr. Al Attas went on to a post-doctoral prosthodontics program at Saudi Commission for Health Specialties in 2012. He also became an ABOI/ID Diplomate in 2017.



Timothy J. Armanini, DDS, Erie, PA, received a dental degree in 1983 from Virginia Commonwealth University. Then in 1987, Dr. Armanini pursued an Oral & Maxillofacial Surgery program at the University of Kentucky. He has been a Diplomate of the American Board of Oral Implantology/Implant Dentistry since 2006.



Richard Allan Assing DDS, Brandon, FL, graduated from Baylor College of Dentistry in 1978 and completed the Puerto Rico MaxiCourse® in 2010. He is a Diplomate of the ABOI/ID (2005).



Jason John Battah, DMD, Montreal, QC, Canada, received his dental degree in 2003 from the Université Laval in Quebec City. Dr. Battah trained in implant dentistry at the 2013 TI-MAX Institute MaxiCourse® and became a Diplomate with the American Board of Oral Implantology/Implant Dentistry in 2016.



Charles Roy Buist, DMD, Irmo, SC, earned his dental degree in 1982 from the University of Alabama. He is a 2016 Diplomate of the ABOI/ID and graduate of the 2007 Georgia MaxiCourse®.



Ward William Clemmons, DDS, Fort Smith, AR, earned his dental degree from University of Missouri at Kansas City in 1986. Dr. Clemmons continued his education in the Puerto Rico MaxiCourse® in 2011. In 2016, he went on to become an ABOI/ID Diplomate.



Joseph Field, DDS, Los Altos, CA, is a 2008 graduate of the University of Southern California, School of Dentistry. Dr. Field became a Diplomate of the American Board of Oral Implantology/Implant Dentistry in 2016.



David A. Goldberg, DMD, North Plainfield, NJ, graduated from Rutgers University in 1979 and completed a General Practice Residency at Montefiore Medical Center the following year (1980). He holds a certificate in periodontics and became Diplomate of ABOI/ID in 2003.



Blayne Gumm, DDS, Belleair Bluffs, FL, received his dental degree at Marquette University in 1976. Dr. Gumm is a Diplomate of the American Board of Oral Implantology/Implant Dentistry (2015).



Douglas G. Hammond, DMD, MSD, Huntsville, AL received his dental degrees from the University of Alabama in 1982 and Indiana University in 1986. Dr. Hammond completed a residency at the VA Medical Center in 1983 and became an ABOI/ID Diplomate in 2008.



Matthew Holtan, DDS, Naples, FL, earned his dental degree at Marquette University in 2010 and completed the 2012 Georgia MaxiCourse®. Dr. Holtan is a Diplomate of the American Board of Oral Implantology/Implant Dentistry, class of 2016.



Aleksandar Janic, DDS, Vancouver, BC, Canada, received his dental degree from the University of Belgrade in 1989. In 2002, Dr. Janic completed the AAID's MaxiCourse® located in New York. He became an ABOI/ID Diplomate in 2004.



Nicolas Lafrance, MDS, Saint-Bruno-de-montarville, QC, Canada, received his dental degree in 2000 from Universite de Montreal. Dr. Lafrance also went on to complete a residency program in 2001. In 2014, he became an ABOI/ID Diplomate.



Jane F. Martone, DDS, Westfield, MA, attended Marquette University where she received her dental degree in 1968. Dr. Martone then completed a General Practice Residency in 1969 at the Western Massachusetts Hospital. Dr. Martone became an ABOI/ID Diplomate in 2016.



Michael Sanders, DDS, DMD, MSC, Eagle River, AK, received a dental degree from Boston University in 2001. The following year, Dr. Sanders completed a General Practice Residency in the United States Armed Forces. In 2016, he became an ABOI/ID Diplomate.



Michael Kolodychak, DMD, Erie, PA, graduated from the School of Dentistry at the University of Pittsburgh in 1996. In 2000, he earned certificate from St. Francis Medical Center in Oral and Maxillofacial Surgery. He is a Diplomate of the American Board of Oral Implantology as of 2006.



Diane Land, DMD, Tucson, AZ, obtained her dental degree in 1990 from the University of Michigan. She went on to finish her Post-Doctoral education at Marquette University in 1993. Dr. Land completed the 2013 Las Vegas MaxiCourse® and also became a Diplomate with the American Board of Oral Implantology in the same year.



Myrna Pearce, DDS, Port Coquitlam, BC, Canada, completed a dental degree at the University of British Columbia in Vancouver in 1985. Dr. Pearce is a 2011 graduate of the Vancouver MaxiCourse® and became a Diplomate of the American Board of Oral Impantology/ Implant Dentistry in 2016.



Oender Solakoglu, DMD, Hamburg, Germany, earned his dental degree from the University of Hamburg in 1998. Dr. Solakoglu then finished the Master of Clinical Dentistry in Periodontology program at the Univerisity of London in 2010. He has been a Diplomate with the American Board of Oral Implantology/Implant Dentistry since 2009.



Eldo Koshy, DMD, MPH, Cochin, India, attended Government Dental College where he earned his dental degree in 2000. Dr. Koshy trained in implant dentistry at the Asia MaxiCourse® in 2006.



Victor Manon, DDS, Kingwood, TX, received his dental degree from the University of Texas at Houston in 1988 and completed a Oral and Maxillofacial Surgery program at the University of Texas in 1992. Dr. Manon has been an ABOI/ID Diplomate since 2005.



Manouchehr Pouresmail, DMD, Paso Robles, CA, graduated from the Endodontics program at Loma Linda University in 2003. He also received a Master of Science in Implant Dentistry at Loma Linda in 2008 and in 2011, became an ABOI/ID Diplomate.



Robert Stanton, DMD, DDS, PhD, Kingwood, TX, received dental degrees from Washington University in 1984 and the University of Texas in 1992. In 2002, he became an ABOI/ID Diplomate.



H. Sam Tadros, DDS, Largo, FL, received a dental degree from University of the Pacific in 1988. He completed the Georgia MaxiCourse® in 1998 and the Prosthodontics program at the University of Pittsburgh in 1992. He became an ABOI/ID Diplomate in 2007.



Kaz Zymantas, DDS, Naperville, IL, received his dental degree in 1979 from Loyola University Chicago, School of Dentistry. Dr. Zymantas trained in the 2005 Georgia MaxiCourse®. In 2016, he became an ABOI/ID Diplomate. ●

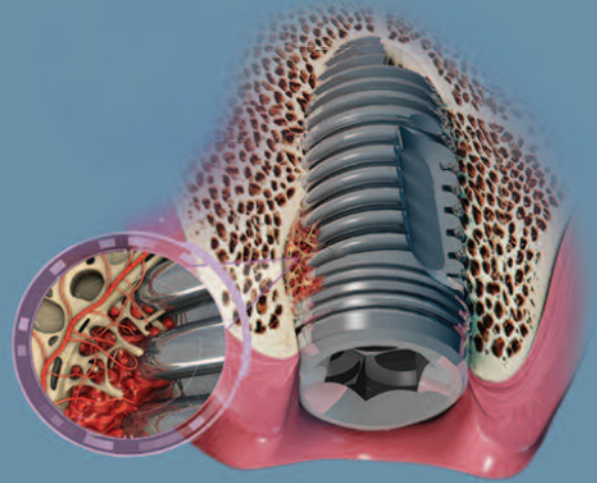


Pierre Joseph Tedders, DDS, Jackson, MI, is a 1999 graduate of the University of Detroit Mercy, School of Dentistry and a 2011 graduate of the Georgia MaxiCourse®. He became an ABOI/ID Diplomate in 2015.



The ESi™ Implant

U.S. Patent No. 9,387,027 B2



Introductory Special Offers*

*One order per dental practice

10 implants + free surgical kit =
\$1,450

or 20 implants + free surgical kit =
\$1,950



Regular price of:
Implant \$189
Surgical Kit \$2,200



Go to www.spiraltech.com
or call 312-440-7777 now
to learn more about
our special offers.

newmembers

The AAID is pleased to welcome the following new members to the Academy. The following members joined between September 13, 2017 and November 24, 2017. If you joined the Academy recently and your name does not appear, it will be listed in the next issue.

The list is organized by state and then alphabetically by city.

International member list is organized by country, province (if available), and city.

Contact your new colleagues and welcome them to the Academy.



ALASKA

Scott Brookshire
Craig

ARIZONA

Darren Reed Brower, DMD
Chino Valley

CALIFORNIA

Omid Fard
Alamo
Dina Gaggi, DDS
El Cajon
Younes Jonah Tabrizi
El Dorado Hills
Gregory Smith
Encinitas
Joseph Miller
Grass Valley
Pirouz Shahbazian, DDS
Los Angeles
Eric M. Barrientos, DDS
Mountain View
Larry Hoyt
Murrieta
Shaghayegh Tahririan, DMD
San Diego
Darryl Torculas, DDS
San Diego
Danny Truong, DDS
San Diego
Martin Chin, DDS
San Francisco
Albert Oh, DDS
San Gabriel
Sophia Rozov
Tarzana
Andrey Rossius, DMD
Westlake Village

COLORADO

Ashley Parker, DDS
Aurora
Brandt D Jones
Castle Rock
Abraham K. Thomas, DMD
Colorado Springs

CONNECTICUT

Phuong Thanh Nguyen Nhu,
DMD
Danbury
Christian O'Connor, DMD
North Haven

FLORIDA

Alissa Hokulani Brewer, DMD
Destin

GEORGIA

Leo Eliezer, DMD
Alpharetta
Gary Chike
Buford

ILLINOIS

Sam Ames
Chicago
Ryan Gerts, DMD
Downers Grove
Michael Lovda, DDS
Hoffman Estates

IOWA

Eric Shelton, DDS
Decorah

KENTUCKY

Jonathan Mark Hardy, DMD
Somerset

LOUISIANA

Benjamin A Beach
Shreveport

MAINE

Aatif Ansari, DDS
Ellsworth

MASSACHUSETTS

Mark Medeiros
Dedham

MINNESOTA

Sean Fleming
Aitkin

MISSOURI

Samir Patel
Thayer

NEBRASKA

Robert Bundy
Ashland
Arielle Brinkman, DDS
Ord

NEVADA

Galya Dumitrean Raz, DMD
Henderson

NEW JERSEY

Paul Sauchelli, DMD
Brookside
Tripti Shetty, DDS
East Brunswick
Dhara Shah, DDS
Jersey City
Amir Fakhrzadeh, DMD
Newark

Sungmin E. Row
Palisades Park
Kerry Kareta, DMD
Summit

NEW MEXICO

Devon L. Rasmussen, DDS
Albuquerque

NEW YORK

Richard C Heintz
Buffalo
Gargi Gajera, DMD
Glenoaks
Craig Heins, DDS
Plattsburgh

NORTH CAROLINA

Khalil Mjehed
Monroe

OHIO

Alexander Gamber
Kettering
Jessica Kile, DDS
Mechanicsburg

OKLAHOMA

David Lawrence, DDS
Oklahoma City

PENNSYLVANIA

Marc Clayton, DMD
Beaver

PUERTO RICO

Francisco Jose Carrillo
San Juan

SOUTH DAKOTA

Matt Nehl, DDS
Belle Fourche

TENNESSEE

Neil Johnson, DDS
Memphis

TEXAS

Anthony Benjamin Gonzalez
Corpus Christi
Michael Shelby, DMD
Fort Worth

UTAH

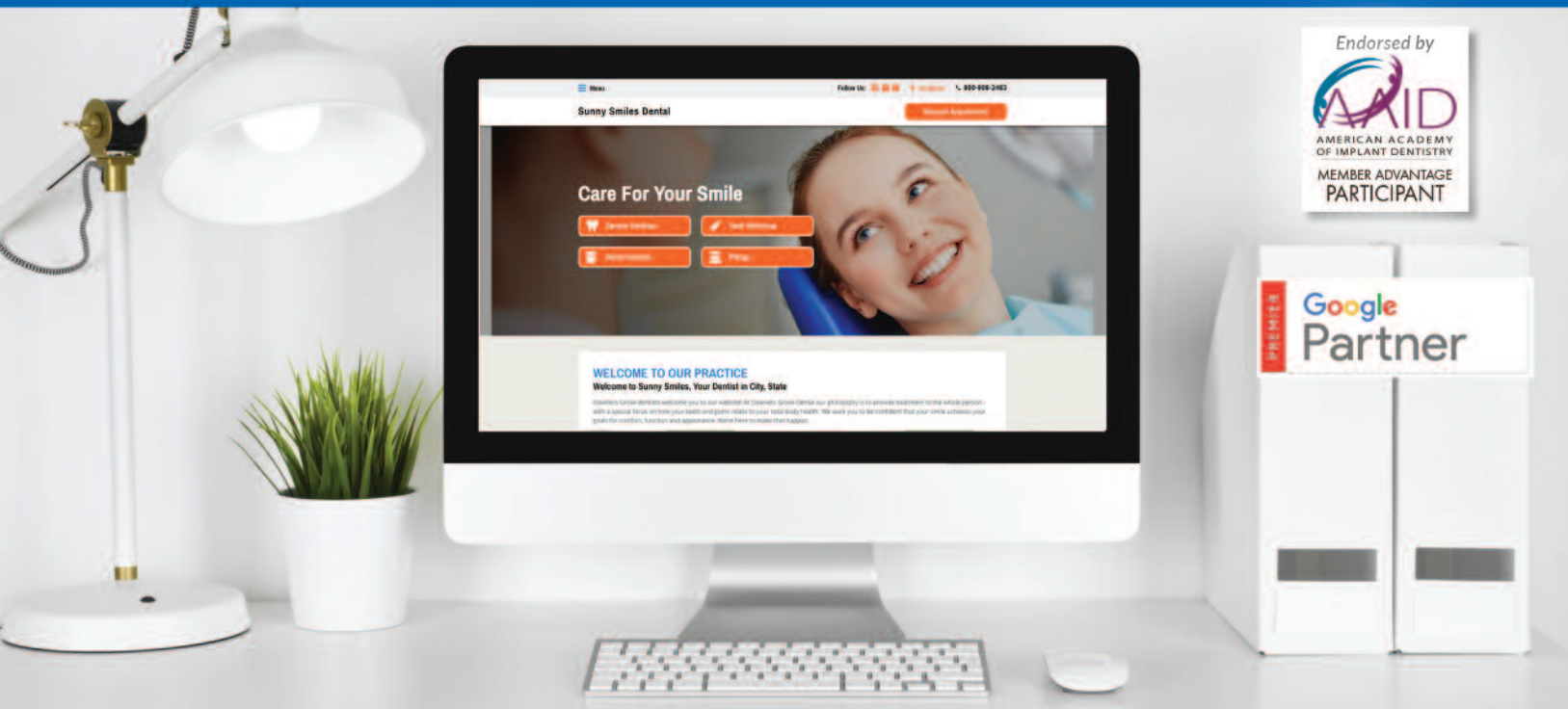Riley D. Clark, DMD
Heber City

VIRGINIA

John A. Marino, DDS
Annandale
Bradley Delph
Charlottesville

[see New Members p. 70](#)

IS YOUR WEBSITE READY FOR 2018?



Call 877-853-6798 to receive your
FREE Website Review and Health Check Report

GET YOUR FREE WEBSITE
HEALTH CHECK TODAY



1. CALL YOUR WEB PRESENCE ADVISOR

They're here to help your practice be the best it can be. Give them your website's address, and they'll use sophisticated diagnostic tools (and years of experience) to assess your strengths and potential weaknesses.



2. REVIEW YOUR RESULTS

After diagnostics are complete, you'll receive a detailed report. Your Web Presence Advisor will help break it down step by step, so you'll know exactly where you stand.



3. MAKE A PLAN OF ACTION!

Now that you have all the important information, what happens next? Whether you want better search engine rankings or stronger online reviews, we'll help you set goals and give you the tools you need to reach them.

CONTINUING EDUCATION BITE



U.S. and Canada AAID MaxiCourses®

Augusta University/AAID MaxiCourse®

Augusta, GA
Co-Director(s): Michael E. Pruett, DMD,
and Douglas Clepper, DMD
March through November
Contact Name: Erica Schlachter
Email: eschlachter@augusta.edu
Phone: 800-221-6437 or 706-721-3967
Website: www.georgiamaxicourse.com

Chicago Midwest AAID MaxiCourse®

Chicago, IL
Co-Directors: Natalie Wong, DDS, and
Adam Foleck, DMD
June – August
Contact: Linda Shoullice
Phone: 416-566-9855
Email: linda@ti2inc.com
Website: www.chicagomaxicourse.com

Las Vegas MaxiCourse®

Englewood, NJ
Director: John Minichetti, DMD
Co-Director: Shanker Iyer, DDS, MDS
Contact: Esther Yang
Email: esther.englewooddental@gmail.com
Phone: 201-871-3555
Website: www.aaid-maxicourse.org

Loma Linda University/AAID MaxiCourse®

Loma Linda, CA
Director: Jaime L. Lozada, DMD
Co-Director: Mathew T. Kattadiyil, DDS,
MDS, MS
March – December
Contact: Annabelle Galvan
Email: lgalvan@llu.edu.com
Phone: 909-558-4685
Website: llumaxicourse.com

New York MaxiCourse® in Implant Dentistry

Bronx, NY
Co-Directors: John Minichetti, DMD, and
Joseph C. D'Amore, DDS
Contact: Esther Yang
Email: esther@englewooddental.com
Phone: 201-871-3555
Website: www.aaid-maxicourse.org

Nova Southeastern University Implant MaxiCourse®

Fort Lauderdale, FL
Director: Jack Piermatti, DMD
October – June
Contact: Linnette Dobbs-Fuller
Email: flinnett@nova.edu
Phone: 609-314-1649
Website: www.dental.nova.edu/ce/courses/
2017-2018/maxi-implant-course.html

Oregon-AAID Implant MaxiCourse®

Eugene, OR
Director: Shane Samy, DMD
September – June
Contact: Jamie Christianson
Email: jamie.maxicourse@gmail.com
Phone: 800-603-7617
Website: www.oraaidmaxicourse.com/

Puerto Rico MaxiCourse® and Clinical Residency in Implant Dentistry

San Juan, PR
Director: Hilt Tatum, DDS
Co-Director: Jose Pedroza, DMD, MSC
September – June
Contact: Miriam Montes
Email: maxicourse@gmail.com
Phone: 787-642-2708
Website: www.theadii.com

Rutgers University of Dental Medicine MaxiCourse®

Newark, NJ
Director: Jack Piermatti, DMD
September – June
Contact: Janice Gibbs-Reed, MA, CMP
Email: gibbs@sdm.rutgers.edu
Phone: 973-972-6561
Website:
sdm.rutgers.edu/CDE/MaxiCourse

TexMAX® Dental Implant Education MaxiCourse®

League City, TX
Director: Jay Elliott, DDS
November – October
Contact: Jackie Martinez
Email:
Jackie@texasimplantededucation.com
Phone: 281-703-9468
Website: www.texasimplantededucation.com

Ti-MAX Implant Maxicourse®

Waterloo, ON
Director: Rod Stewart, DDS
Co-Director: George Arvanitis, DDS
September – June
Contact: Chantel Furlong
Phone: 905-235-1006
Email: info@timaxinstitute.com
Website: www.timaxinstitute.com

AAID Vancouver MaxiCourse®

Vancouver, BC
Director: William Liang, BSc, DMD
September – June
Contact: Andrew Gillies
Email: andrew@implant.ca
Phone: 604-330-9933
Website: www.vancouvermaxicourse.com

Washington, D.C. (Mid-Atlantic) MaxiCourse®

Washington, D.C.
Director: Bernee Dunson, DDS
March – December
Contact: Keonka Williams
Email: dcmxi@dunsondental.com
Phone: 404-897-1699
Website: www.dcmximaxicourse.com

Outside U.S. and Canada MaxiCourses®

Japan MaxiCourse®

Nagoya, Japan
Director: Yasunori Hotta, DDS, PhD
December – November
Email: hotta-dc@ff.ij4u.or.jp
Phone: +81-52-794-8188
Website: www.hotta-dc.com

MaxiCourse® Asia

Abu Dhabi, United Arab Emirates
New Dehli, India; Bangalore India
Contact: Shankar Iyer, DDS, MSD
March – November (UAE)
February – TBD (Bangalore)
Contact: Prithivi Belapur
Email: drsyedkhalid@hotmail.com
Website: www.maxicourseasia.com

Korea MaxiCourse®

Gyeonggi-do, South Korea
Director: Jaehyun Shim, DDS
March – December
Contact: Kyungim Yeom
Email: ykimichelle@gmail.com
Website: www.koreamaxicourse.com

Egypt MaxiCourse®

Cairo, Egypt
Co-directors: Kim Gowey, DDS;
Shankar Iyer, DDS, MDS
April – May
Contact: Dr. Mahmoud Kohail
Email: mahmoudkohail@ascde.com
Phone: (002) 01141403350
Website: www.ascde.com/program/maxi

China MaxiCourse®

Shanghai, China
Director: Jaime Lozada, DMD
Co-Director: Joey Chen, DDS, MS
July – March
Contact: Joey Chen
Email: anshindental@gmail.com
Phone: +86 21-61364635 or 909-558-4685
Website: www.college.dental360.cn/
zhongzhim

MaxiCourse® Malta

Kalkara, Malta
Co-Directors: Dennis Flanagan, DDS,
MSc; Shankar Iyer, DDS, MDS
March – TBD
Contact: Dennis Flanagan
Email: dffdds@comcast.net
Website: www.maxicoursemalta.com

Courses presented by AAID credentialed members*

U.S. LOCATIONS

24 Hour Teeth

Spring Hill, FL
September 21 – 22, 2017
January 25 – 26, 2018
March 29 – 30, 2018
Contact: James W. Gibney, DMD, JD
Phone: 352-686-4223
Email: jwgibney@atlantic.net
Website: jameswgibneydmd.com

Basic and Advanced Implant Mini- Residency in Surgery & Pros. and Live Surgery Weekend

John C. Minichetti, DMD
Contact: Esther Yang
Phone: 201-871-3555
Email: info@englewooddental.com
Website: www.dentallearningimplant
center.com/ce-courses

California Implant Institute

1 Year Comprehensive Program in Implant
Dentistry
San Diego, CA
4 sessions; 5 days each
300 CE credits
Dr. Louie Al-Faraje, Academic Chairman
LIVE patient courses also offered by the
Institute
Phone: 858-496-0574
Email: info@implanteducation.net
Website: www.implanteducation.net

Foundations in Implant Dentistry

Dr. Michael Gillis
Session 3: April 5 – 7, 2018
Halifax, Nova Scotia
Contact: Denise Robicheau
Phone: 902-405-0077
Email: admin@gillisdentalimplants.com

Laser Pocket Reduction & Diode Training for the Dental Professional

Sioux Falls, SD
Edward Kusek, DDS
Contact: Kristi Meyer
Phone: 605-371-3443
Website: www.drkusek.com/courses.html

Live Surgical Prettau Zirconia Implant Bridge Course

Michael Tischler, DDS; Scott Ganz, DMD;
Claudia Patch, DMD
Tischler Dental Laboratory
Woodstock, NY
Contact: 845-679-2737
Website: www.prettau-course.com

Midwest Implant Institute

Drs. Duke & Robert Heller
Advanced Courses:
(305) Implant Prosthetics
(601) Bone Grafting & Sinus Elevation
(602) Digging Out of Problems
Contact: 614-505-6647
Email: lisa@implantdentist.org
Website: www.midwestimplantinstitute.com

Mini Residency

Director: Shankar Iyer, DDS, MDS
September – June, Bi-weekly
100 hours CE credit
Approved by NJ State Board of
Dentistry
Contact: Dr. Shankar Iyer
Email: drsiyer@aol.com
Website: www.smileusa.com/
mini-residency-us

Pikos Implant Institute

Michael A. Pikos, DDS
Soft Tissue Grafting
Sinus Grafting
Advanced Bone Grafting
Guided Full-Arch Immediate Implant
Reconstruction
Contact: Alison Thiede
Phone: 727-781-0491
Email: learn@PikosInstitute.com
Website: www.pikosinstitute.com/
programs-and-courses/course-
continuum-overview/

University Implant Educators

Director: Francis Jones, DDS, MBA,
AFAAID
San Diego, CA
1,3,4 Day Courses
All Courses are intensive surgical
externships with live patient care.
Contact: Grace Terranova
Phone: 877-709-6623
Email:
info@universityimplanteducators.com
Website:
www.universityimplanteducators.com/
implantology-courses-schedule

CANADA

The D.M. Vassos Dental Implant Centre Introductory & Advanced Surgical & Prosthetic Programs

Dr. D.M. Vassos
Mentor Program – Hands-on Program over
six Saturdays
Location: Edmonton, Alberta, Canada
Contact: Rosanna Frey
Phone: 780-488-1240
Email: rosanna@dmvassos.com
Website: www.dmvassos.com

The BITE Club

For those not ready for the AAID
Vancouver MaxiCourse®. Didactic study
club to introduce you to the world of
oral implantology.
Contact: Andrew Gillies, Education
Coordinator
Phone: 604-330-9933
Email: andrew@implantconnection.ca
Website: www.thebiteclub.ca

“Hands-On” Introductory to Advanced Surgical and Prosthetic Implant Courses with Live Surgery.

Dr. Robert E. Leigh, Director
Year-round, Custom Tailored and 5-DAY
MINIRESIDENCY Courses
Location: Leigh Smile Center, Alberta,
Canada
Contact: Corie Zeise
Phone: 1-888-877-0737 (Toll Free)
Email: coriemanager@gmail.com
Web Sites: www.leighsmilecenter.com

Implant Connect: Prosthetic Course

William Liang, DMD, Director
One-year program that will cover patient
selection, treatment planning, occlusal
considerations and how to incorporate
implants into your practice.
Email: andrew@implantconnection.ca
Website: www.cditc.ca

Pacific Implant Institute

Dr. Ron Zokol
Comprehensive Training in Implant
Dentistry
September through June
Location: Vancouver, B.C., Canada
Contact: Kim
Phone: 1-800-668-2280
Email: kimber@piidentistry.com
Website: www.piidentistry.com

see Continuing Education p. 68

Continuing Education

continued from page 67

Toronto Implant Institute

Toronto Implant Institute
Natalie Y. Wong, DDS, FAAID, DABOI/ID
Implant Prosthetic Session: Traditional to Digital

Digital Implant Dentistry Internship
Guided Surgery and Guided Prosthetics™
for Immediate Full-Arch Implant Restorations

Contact: Linda Shouldice
Phone: 416-566-9855
Email: linda@ti2inc.com
Website: www.ti2inc.com

Vancouver Implant Continuum

Continuing your MaxiCourse® journey
One-year program that incorporates live patient surgery on your own patients with a review of everything within the AAID Vancouver MaxiCourse®

Contact: Andrew Gillies, Education Coordinator
Phone: 604-330-9933
Email: andrew@implantconnection.ca
Website: www.cditc.ca

OUTSIDE NORTH AMERICA LOCATIONS

Beirut Implant Dentistry Center

CE Courses Survey of Surgical and Prosthetic Implant Care

Drs. Jihad Abdallah & Andre Assaf
Contact: Mahia Cheblac
Phone: +961 1 747650 or +961 1 747651
Fax: +961 1 747652
Email: beirutidc@hotmail.com

AAID Active Study Clubs*

US/CANADA

Calderon Institute Study Club

Location: Queens, NY /Oceanside, NY
Director: Mike E. Calderón, DDS
Contact: Andrianna Acosta
Phone: 631-328-5050
Email: calderoninstitute@gmail.com
Website: www.calderoninstitute.com

Acadiana Southern Society

Location: Lafayette, LA
Director: Danny Domingue, DDS
Website: www.acadianasouthernsociety.com/upcoming-meetings.html

DHII Study Club of Georgia

Location: Atlanta, GA
Director: David Han, DDS, MS
Contact: Frank Butler
Email: drfrankbutler@bellsouth.net
Website: www.dhii.org/our-fees

AICHI IMPLANT CENTER

Location: Nagoya, Aichi-Ken, Japan
Director: Yasunori Hotta, DDS, PhD
Website: www.hotta-dc.com/
Hughes Dental Implant Institute and Study Club

Location: Sterling, VA
Director: Richard E. Hughes, DDS
Contact: Victoria Artola
Email: dentalimplant201@gmail.com

SMILE USA® Center for Educational Excellence Study Club

Location: Elizabeth, NJ
Director: Shankar Iyer, DDS, MDS
Contact: Terri Baker
Phone: NA
Email: dentalimplant201@gmail.com
Website: NA

Implant Study Club of North Carolina

Location: Clemmons, NC
Director: Andrew Kelly, DDS
Contact: Shirley Kelly
Phone: 3364143910
Email: shirley@dentalofficesolutions.com
Website: www.dentalofficesolutions.com

Vancouver Implant Continuum

Location: Surrey, BC, Canada
Director: Williams Liang, DMD
Contact: Andrew Gillies
Phone: 604-330-9933
Email: andrew@implant.ca
Website: www.vancouvermaxicourse.com/implant-continuum

Monmouth Dental Implants Study Group

Location: Lincroft, NJ
Director: Richard Mercurio, DDS
Contact: Marth Gatton
Phone: NA
Email: marty@lincroftvillagedental.com
Website: www.Lincroftvillagedental.com

AAID Bergen County Dental Implant Study Group

Location: Englewood, NJ
Director: John Minichetti, DMD
Contact: Lisa McCabe
Phone: 2019260619
Email: lisapmccabe@gmail.com

Hawaii Dental Implant Study Club

Location: Honolulu, HI
Director: Michael Nishime, DDS
Contact: Kendra Wong
Phone: NA
Email: mnishimedds@gmail.com
Website: www.honoluludentaloffice.com

Mid-Florida Implant Study Group

Location: Orlando, FL
Director: Rajiv Patel, BDS, MDS
Contact: Director
Phone: 386-738-2006
Email: drpatel@delandimplants.com
Website: NA

AAID Lake Superior Implant Study Club

Location: Ada, MN
Director: David Resnick, DDS
Contact: Director
Phone: 218-784-7119
Email: ddz@arvig.net

Korean Dental Implant Institute

Location: Seoul, Korea
Director: Jaehyun Shim, DDS
Contact: Kyungim Yeom
Phone: +82 10 2716 7249
Email: ykimichelle@gmail.com
Website: www.kdi-aaid.com

Alabama Implant Study Club

Location: Brentwood, TN
Director: Sonia Smithson, DDS
Contact: Norma Jean Applebaum
Email: docnj4aisg@aol.com
Website: alabamaimplant.org

INTERNATIONAL

Cyprus implant Study Club

Location: Nicosia, Cyprus
Director: Nicolas Papadopoulos, DDS
Contact: Director
Phone: +99606565
Email: Info@nicosiadentalcenter.com

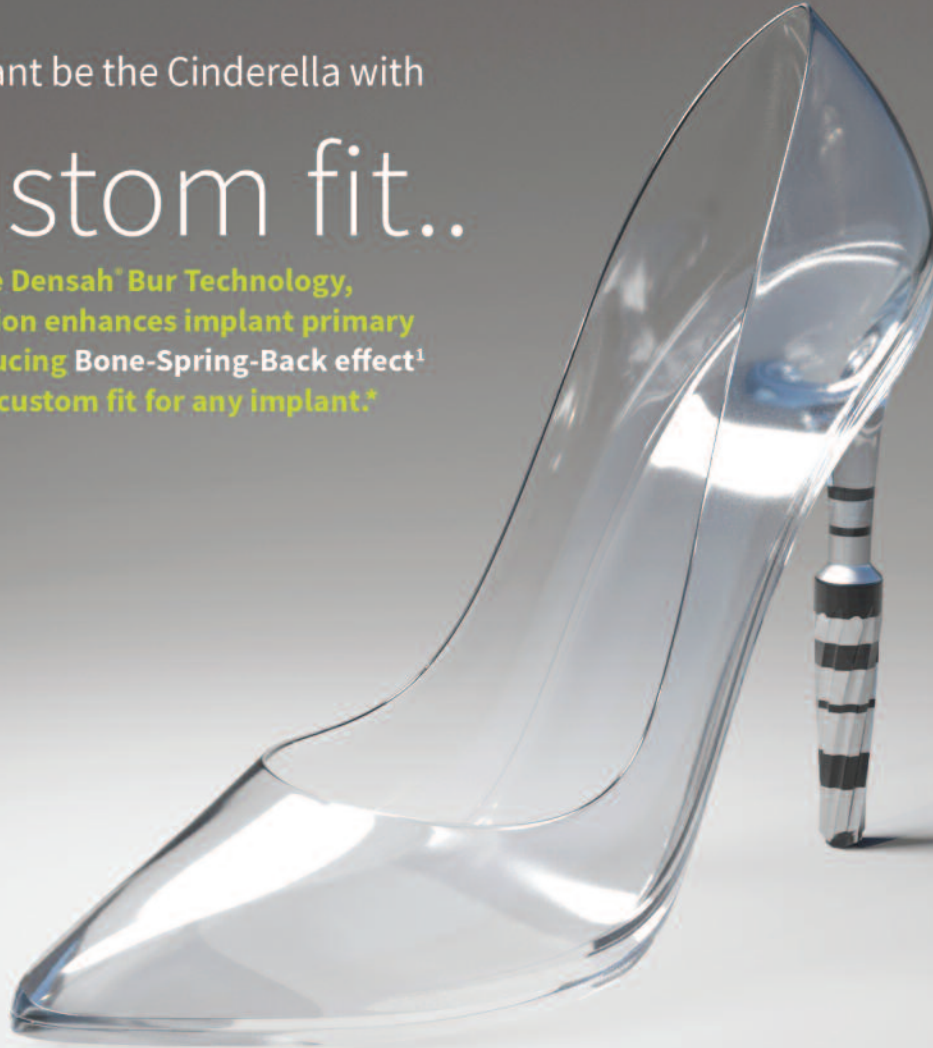* This calendar section is available to any credentialed member of the AAID to post information about implant education courses offered by the member. The member must agree to provide the list of attendees to AAID in exchange for publication of the course in the calendar. Study Club listings are available only to Affiliated AAID Study Clubs. For information about becoming an Affiliated AAID Study Club, email education@aaid.com.



Experience the Difference

Let any implant be the Cinderella with
a custom fit..

Utilizing the Densah[®] Bur Technology,
Osseodensification enhances implant primary
stability by producing Bone-Spring-Back effect¹
to facilitate a custom fit for any implant.*




Any Implant*, Any Ridge, In Either Jaw

¹Huwais S, Meyer EG. A Novel Osseous Densification Approach in Implant Osteotomy Preparation to Increase Biomechanical Primary Stability, Bone Mineral Density, and Bone-to-Implant Contact. Int J Oral Maxillofac Implants 2017;32:27-36.

*In accordance with the densifying reference guides on versah.com/densifying-reference-guide

©2017 Huwais IP Holdings LLC. All rights reserved.
Versah and Densah are registered trademarks of Huwais IP Holdings LLC. HT026 REV01

versah.com  

 Enhance the Host

New Members

continued from p. 64

WASHINGTON

Jeff S. Schroeder
Pasco
Pavinee Chotiwanaporn,
MSC
Seattle

CANADA

ALBERTA
Ali Afshar, DDS
Edmonton

SASKATCHEWAN

Anthony Romaniuk
White City

INDIA

Syed Saquib Umar
New Delhi

ITALY

Alessandro Parrella
Cittiglio

PHILIPPINES

Maria Theresa Villareal
Mendoza
San Juan

ROMANIA

Bogdan Calenic
Bucharest

SAUDI ARABIA

Mohamad Mahmoud
Awadalla, PhD(ca)
Riyadh
Muhanad Abdulkareem
Alhaj
Riyadh

SOUTH KOREA

Bae Sung-Woo
Jeonju city
Seung-Hui Lee, DDS
Busan

Hyung Suk Oh
Buyen

Minho Choi PhD
Daejeon
Kiwoong Jang, DDS
Gyeonggi

Seungsun Baek
Seoul

Sang Yun Kim
Seoul

TRINIDAD AND TOBAGO

Safaaz Khayyam
Mohammed, DDS
Chaguanas

UNITED ARAB EMIRATES

Srikanth Narkedamalli BDS
Abu Dhabi

American R&D Institute of Implantology	72
Bicon.....	60
Biohorizons.....	2
California Implant Institute	31
Dental Implant Technologies.....	6,7
Gilleard Dental Marketing	51
Glidewell Laboratories	9
Hybridge	27
Neodent-Straumann	47
OCO Biomedical	44
Officite	65
Pacira.....	41,42
Preat Corp	49
SpiralTech	63
Tatum Surgical	11
Teeth Tomorrow	25
Treloar and Heisel.....	71
University at Buffalo School of Dental Medicine	39
Versah.....	69
Washington, DC Maxicourse®.....	55

CONNECT WITH AAID

Facebook.com/aaidimplantdentists

Twitter.com/aaid_dentists

www.linkedin.com/company/american-academy-of-implant-dentistry

AAID NEWS is a quarterly publication of the American Academy of Implant Dentistry. Send all correspondence regarding the newsletter to AAID, 211 East Chicago Avenue, Suite 750, Chicago, IL 60611 or by email to editor@aaid.com. Please notify AAID and your postmaster of address changes noting old and new addresses and effective date. Allow 6-8 weeks for an address change.

The acceptance of advertising in the AAID News does not constitute an endorsement by the American Academy of Implant Dentistry or the AAID News. Advertising copy must conform to the official standards established by the American Dental Association. Materials and devices that are adver-

tised must also conform to the standards established by the United States Food & Drug Administration's Sub-Committee on Oral Implants and the American Dental Association's Council on Dental Materials and Equipment Acceptance Program.

It is the policy of the American Academy of Implant Dentistry that all potential advertisements submitted by any person or entity for publication in any AAID media must be deemed consistent with the goals and objectives of the AAID and/or ABO/ID, within the sole and unbridled discretion of the AAID and/or ABO/ID. Any potential advertisement deemed to be inconsistent with the goals and/or objectives of the AAID shall be rejected.



Treloar
& Heisel

FINANCIAL SERVICES FOR THE
DENTAL AND MEDICAL PROFESSIONAL

Call 800.345.6040
www.treloaronline.com



**Finally, a company that truly
understands the needs of dentists.**

Patients seek your help because of your specialty expertise. Similarly, as a dentist you want to work with a financial company that understands your particular risk management needs. **When it comes to disability income, business overhead, and long term care insurance, Treloar & Heisel is your guide every step of the way.**

Investment Advice offered through WCG Wealth Advisors, a Registered Investment Advisor. TH-160011

Inaugural Global Symposium

The Present and Future of Implantology

May 17th-19th, 2018

Hilton Toronto
Toronto, Ontario, Canada

Receive up to 24 CE Credits



ARDII is designated as an Approved PACE Program Provider by the Academy of General Dentistry. The formal continuing education programs of this program provider are accepted by AGD for Fellowship/Mastership and membership maintenance credit. Approval does not imply acceptance by a state or provincial board of dentistry or AGD endorsement. The current term of approval extends from 9.1.17 to 8.31.19. Provider ID# 378964

Powered by



Register now at www.ardii.org or call 847.677.7777



Gordon Christensen, DDS, MSD, PhD



Joe Massad, DDS




Carl Driscoll, DMD, FACP



Ralf Smeets, MD, DDS, PhD



Tomas Linkevicius, DDS, PhD



Bryan Jacobs, DMD, MS



Hasan Aydilek, DDS, MSc



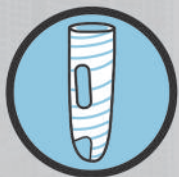Russell Baer, DDS



Marc Hansen, DDS, MS



Marco Josch, DDS



Lecture & Hands-On

Global experts will share their research and knowledge on:

- Cementitis & Zero Bone Loss
- Implantology & Cosmetic Materials
- Single Tooth Integration of 3D Design & CAD/CAM Solution
- and many other cutting-edge subjects



Downtown Hotel Info

Hilton Toronto
145 Richmond Street West
Toronto, ON M5H 2L2 Canada

ARDII Symposium rate is CAD \$229 per night

For more information on the hotel, please visit www.ardii.org.



Pricing (USD)

	Thursday & Friday			Saturday
	Doctors	Students	Lab Techs	Hands-On
Early Bird	\$345	\$225	\$275	\$160
Standard	\$395	\$295	\$345	\$180